

CASE REPORT

Oral Fibrolipoma of Oral Cavity

¹Vinay Hanumanthrao Vadvadgi, ²Rajiv Saini

ABSTRACT

Fibrolipoma, a benign tumor, is classified as a variant of conventional lipoma. It usually presents as a soft, smooth-surfaced nodular masses that can be sessile or pedunculated. Most of them are less than 3 cm in size, but it can become much larger. The buccal mucosa and buccal vestibule are the most common intraoral sites. Here, we present a new case of this uncommon oral lipofibroma that presented on the maxillary attached gingiva.

Keywords: Fibrolipoma, Tumor, Lipoma.

How to cite this article: Vadvadgi VH, Saini R. Oral Fibrolipoma of Oral Cavity. *Int J Experiment Dent Sci* 2014;3(2):106-108.

Source of support: Nil

Conflict of interest: None

INTRODUCTION

Fibrolipoma is an uncommon histological variant of the classic lipoma, in which neoplastic fat cells are embedded within dense collagen.¹ Most patients are 40 years of age or older. Lipoma is a benign mesenchymal soft tissue neoplasm of mature adipose tissue.^{2,3} They are relatively rare in the oral cavity, accounting for 1 to 4.4% of all benign tumors.^{4,5} Their etiology and pathogenesis remain unclear, although mechanical, endocrine and inflammatory influences have been reported.⁶ Histologically, lipomas are classified as simple lipoma or variants such as fibrolipoma, spindle cell lipoma, intramuscular or infiltrating lipoma, angioliipoma, salivary gland lipoma (sialoliipoma), pleomorphic lipoma, myxoid and atypical lipomas.¹ Fibrolipoma of the oral cavity has been infrequently reported. It can occur in various anatomic sites including the buccal mucosa, lips, tongue, palate, buccal vestibule, floor of the mouth and retromolar area.⁵ Fibrolipomas have also been reported in the extraoral sites such as esophagus, pharynx, colon, trachea, larynx and other locations.^{7,8} They are well-circumscribed, slow-growing, long standing, painless soft tissue tumors that may be superficially or more deeply located and covered by

normal mucosa.^{2,3,5,6,9} They are usually slow growing and rarely recur after surgical treatment. Hence, the prognosis of these benign tumors is considered good.^{10,11}

CASE REPORT

A 65-year-old female patient reported with a chief complaint of swelling on upper front region of mouth since 2 months. The swelling was first noticed 2 years ago, which showed slow continuous gradual enlargement. The patient had no difficulty in mastication, speech and deglutition. Intraoral examination revealed a pinkish, well-defined oval swelling measuring 2.5 × 3 cm present in the upper anterior region (Fig. 1). On palpation, the swelling was soft, fluctuant, nontender, mobile and the margins were slippery under the palpating finger. A provisional diagnosis of intraoral lipoma was established. Routine blood examination was found to be normal. The lesion was excised under local anesthesia and the excised tissue was sent for histopathological examination (Fig. 2). Microscopic examination revealed adipose tissue with compressed blood vessels embedded within dense collagen fibers. Proliferating fibroblasts were evident in the connective tissue stroma. The overlying epithelium was 8 to 10 layers thick, atrophic, parakeratinized and stratified squamous type. Correlating with the clinical and histopathological examination, the excised lesion was suggestive of fibrolipoma (Fig. 3). The postoperative course was uneventful. No recurrence of the lesion has been observed (Fig. 4).

DISCUSSION

The initial report of oral lipoma was provided in 1848 by Roux in a review of alveolar masses which he referred it as a

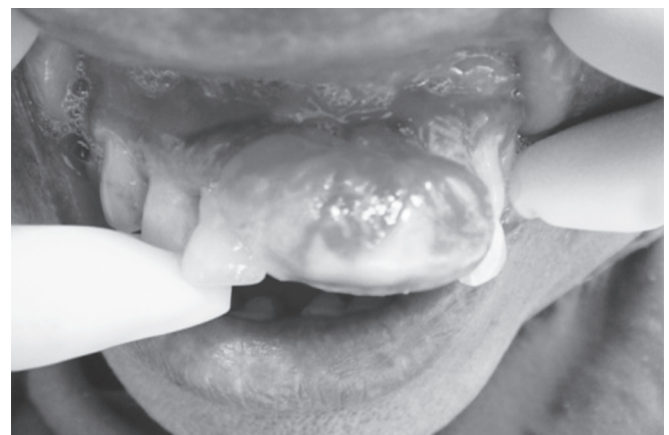

Fig. 1: Clinical case presentation of fibrolipoma

¹Senior Lecturer, ²Associate Professor

^{1,2}Department of Periodontology, Pravara Institute of Medical Sciences, Ahmednagar, Maharashtra, India

Corresponding Author: Vinay Hanumanthrao Vadvadgi Senior Lecturer, Department of Periodontology, Pravara Institute of Medical Sciences, Ahmednagar, Maharashtra India, Phone: 9975626650, e-mail: periodontist29@gmail.com

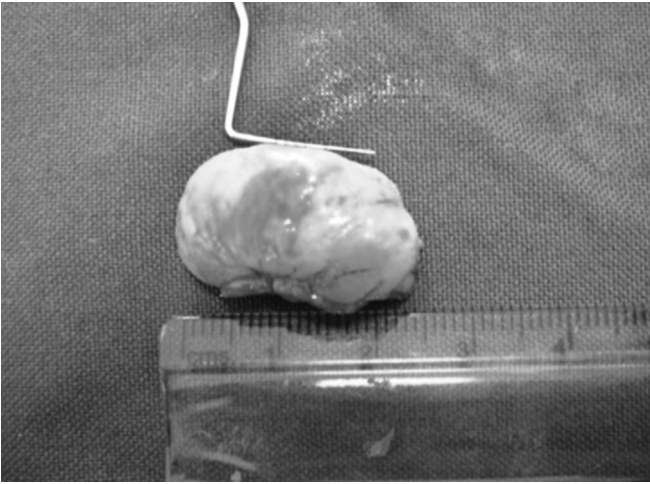

Fig. 2: Excised lesion

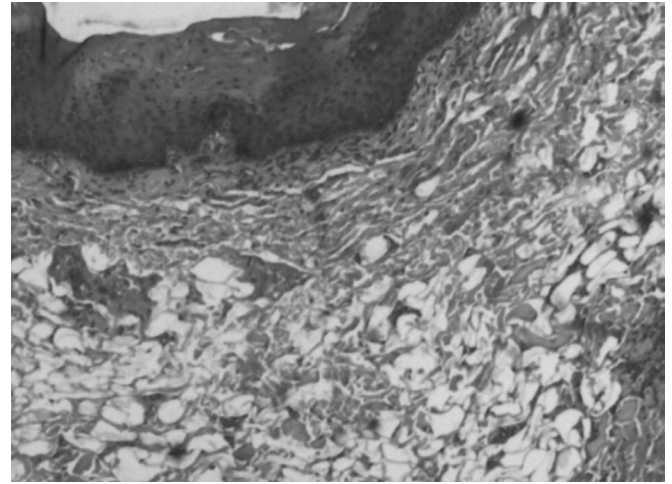


Fig. 3: Histological section

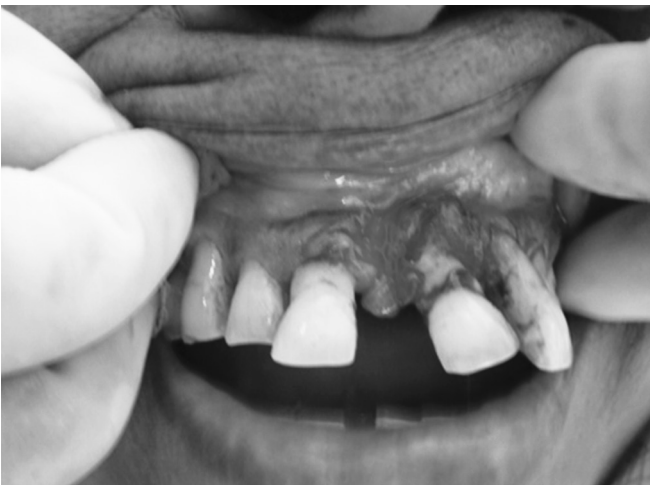

Fig. 4: Postoperative

'yellow epulis'.¹² The lipoma is a very frequent benign tumor of adipose tissue, but its presence in the oral and oropharyngeal region is relatively uncommon with a prevalence rate of only 1/5000 adults.¹ Fibrolipoma is a microscopic variant of lipoma characterized by a significant fibrous component intermixed with lobules of fat cells. The consistency of this lesion varies from soft to firm, depending on the quantity and distribution of fibrous tissue and the depth of the tumor.¹³ The tumor has been reported to be more frequent in the buccal mucosa and buccal vestibule, and it also shows a slight predominance in females.¹⁰ Hereditary, fatty degeneration, hormonal basis, trauma, infection, infarction and chronic irritation are probable representative theories to elucidate the pattern of a lipoma. A number of microscopic variants have been described. The most common of these is the fibrolipoma, characterized by a significant fibrous component intermixed with the lobules of fat cells. The angiolipoma consists of an admixture of mature fat and numerous small blood vessels. Myxoid lipoma exhibits a mucoïd background and may be confused with myxoid liposarcomas. The spindle cell lipoma is another variant that demonstrates variable

amount of uniform appearing spindle cells in conjunction with a more typical lipomatous component. Pleomorphic lipomas are characterized by presence of spindle cells and bizarre hyperchromatic giant cells. Intramuscular lipomas are often more deeply situated and have an infiltrative growth pattern that extends between skeletal muscle bundles. The treatment of lipomas including fibrolipoma is usually surgical excision. This tumor can be life-threatening due to obstruction of upper airway by virtue of its size as sudden asphyxia death has been reported in a case of esophageal fibrolipoma.¹⁰ Lesions outside the oral cavity could show greater recurrence rates after surgical excision, but intraoral intramuscular lipomas, although not well-limited, rarely show recurrence if completely excised.

CONCLUSION

Lipomas found in the oral and maxillofacial region are typically slow-growing lesions. The clinical course is typically asymptomatic until they get larger in size. Most of lipomas develop in the subcutaneous tissues but deeper tissues may be involved as well. The adequate information and timely management of tumors in this region is significant. The total resection should be emphasized, which is the key aspect to avoid recurrence.

REFERENCES

1. Neville BW, Damm DD, Allen CM, Bouquot JE. Oral and maxillofacial pathology. 2nd ed. Philadelphia: Elsevier Publication 2004.
2. Furlong MA, Fanburg-Smith JC, Childers EL. Lipoma of the oral and maxillofacial region: site and subclassification of 125 cases. *Oral Surg Oral Med Oral Path Oral Radiol Endod* 2004; 98(4):441-450.
3. de Visscher JG. Lipomas and fibrolipomas of the oral cavity. *J Maxillofac Surg* 1982;10(3):177-181.
4. Lombardi T, Odell EW. Spindle cell lipoma of the oral cavity: report of a case. *J Oral Pathol Med* 1994;23(5):237-239.

5. Fregnani ER, Pires FR, Falzoni R, Lopes MA, Vargas PA. Lipomas of the oral cavity: clinical findings, histological classification and proliferative activity of 46 cases. *Int J Oral Maxillofac Surg* 2003;32(1):49-53.
6. Aust MC, Spies M, Kall S, Gohritz A, Boorboor P, Kolokythas P, Vogt PM. Lipomas after blunt soft tissue trauma: are they real? Analysis of 31 cases. *Br J Dermatol* 2007;157(1):92-99.
7. Perez B, Campos ME, Rivero J, Lopez-Aguado D. Giant esophageal fibrolipoma. *Otolaryngol Head Neck Surg* 1999;120(3):445-446.
8. Nicoli F, Balli C, Pezza V. A case of giant fibrolipoma of the esophagus. Diagnosis using computerized tomography and double-contrast esophagography. *Radiol Med* 1990;80(1-2):99-102.
9. Greer RO, Richardson JF. The nature of lipomas and their significance in the oral cavity: a review and case report of cases. *Oral Surg Oral Med Oral Pathol* 1973;36(4):551-557.
10. Gupta S, Pathak S. Fibrolipoma of buccal mucosa: a case report. *J Ind Dent Assoc* 2011;5(6):737-738.
11. Rehani S, Bishen KA. Intraoral fibrolipoma: a case report with review of literature. *Ind J Dent Advanc* 2010;2:215-216.
12. Manjunatha BS, Pateel GSD, Shah V. Oral fibrolipoma-a rare histological entity: report of 3 cases and review of literature. *J Dent* 2010;7(4):226-231.
13. Shafer HL. Textbook of oral pathology. In: Rajendran R, Siva-pathasundharam B, editors. *Benign and malignant tumors of the oral cavity*. 6th ed. 2009.