

CASE REPORT

Intrusion of Overerupted Molars by Corticotomy and Fixed Orthodontic Appliances

¹Maria LAH de Souza, ²Rodrigo V Soares, ³Elton G Zenóbio, ⁴Matheus M Pithon, ⁵Dauro Douglas Oliveira

ABSTRACT

In this article, a review of the literature regarding the use of selective alveolar corticotomies (SAC) combined with orthodontic treatment was conducted, and the results of its use in a patient with overerupted maxillary 1st molars are described. Adequate intrusion was obtained within a short period of time, the protocol avoided the necessity of removal of sound tooth structure for crown lengthening, endodontic treatment, and full crown prosthetic restorations. Therefore, the obtained results indicate that SAC/orthodontic use is efficient in the intrusion of overerupted 1st molars and suggest its potential use in the treatment of other malocclusions.

Keywords: Malocclusion, Oral, Surgery, Tooth movement.

How to cite this article: de Souza M LAH, Soares RV, Zenóbio EG, Pithon MM, Oliveira DD. Intrusion of Overerupted Molars by Corticotomy and Fixed Orthodontic Appliances. *Int J Experiment Dent Sci* 2016;5(1):78-82.

Source of support: Nil

Conflict of interest: None

INTRODUCTION

The correction of overerupted maxillary molars is considered one of the most challenging orthodontic procedures because of the difficulty in applying intrusive forces in the appropriate direction. Prolonged treatment time, compared with other types of corrective tooth movement, is another complicating factor, especially in adult patients.^{1,2} Alternative restorative procedures are also available if intrusion is not orthodontically obtained. However, these alternative procedures are complex and more aggressive because most of the time they include removal of sound tooth structure, endodontic treatment, periodontal surgery for crown lengthening, and sometimes full crown prosthetic restorations.²⁻⁴

The use of conventional fixed orthodontic appliances to intrude overerupted maxillary molars may lead to undesired movements of the adjacent teeth, compromising the result and further increasing the treatment time.¹ Other alternatives to correct overerupted upper molars include high-pull headgears,⁵ removable appliances associated with elastics⁶ or magnets,⁷ and modified transpalatal bars.⁸ However, these approaches are technically difficult and usually demand excellent patient cooperation.

Temporary skeletal anchorage devices opened a new frontier in orthodontics as an auxiliary tool to facilitate some challenging orthodontic tooth movements, such as the intrusion of posterior teeth. However, these devices have limitations^{9,10} because they may not be placed in the ideal location when posterior intrusive forces are required.¹¹ In such cases, a combination of orthodontic forces and localized alveolar corticotomies might be considered as an alternative to intrude overerupted maxillary molars.^{1,12}

The combination of alveolar bone corticotomies and orthodontic treatment has been used as an alternative approach to facilitate the treatment of complex malocclusions^{1,12} and/or to decrease the overall treatment time.¹³⁻¹⁵ Although corticotomies are interventions limited to the alveolar bone cortical plate, the resultant surgical wound seems to boost the biological response to the mechanical stimuli applied shortly after the surgery by different orthodontic appliances.^{1,13,16,17} Another possible explanation to this favorable biologic response is that the bone blocks created by the surgical cuts move when heavier orthodontic forces are applied immediately after the surgery.^{18,19}

There are a number of case reports in the literature demonstrating successful posterior teeth intrusion through combined orthodontic forces and alveolar decortifications.^{1,2,20,21} The cases showed a shorter treatment time when compared with conventional orthodontic methods.⁵⁻⁸ However, most of the appliances used in these case reports were removable and strongly relied on patient cooperation. The purpose of this clinical presentation is to describe the successful combination of localized alveolar corticotomy and conventional fixed orthodontic appliances to intrude both maxillary first molars in an adult female patient.

¹⁻⁵Professor

^{1-3,5}Department of Orthodontics, Pontifical Catholic University of Minas Gerais, Belo Horizonte, Minas Gerais, Brazil

⁴Department of Healthy I, Southwest Bahia State University Bahia, Brazil

Corresponding Author: Dauro Douglas Oliveira, Professor Pós-graduação em Odontologia, Pontifícia Universidade Católica de Minas Gerais, Avenida Dom José Gaspar, 500 Prédio 46, Sala 106, Belo Horizonte, MG 30535-610, Brazil e-mail: dauro.bhe@gmail.com

CASE REPORT

A 21-year-old Brazilian woman of mixed ethnic background was referred to the Graduate Orthodontic Clinic of the School of Dentistry, for routine evaluation prior to prosthodontic treatment. The major concerns of the prosthodontist were the overerupted maxillary first molars (Figs 1A and B). The left and right first molars were extruded 4.6 and 2.4 mm respectively.

Intraoral examination revealed that the patient had a mild crowding in the maxillary arch and spacing in the lower arch due to the absence of the mandibular second premolars and the left first molar. The poor dental care and the absence of the lower teeth contributed to the overeruption of the maxillary first molars. She had a class II deep bite malocclusion, with the upper midline coincident with the face and the lower midline slightly shifted to the right. There were no relevant skeletal or facial discrepancies and no signs and symptoms of temporomandibular joint disorders. Her medical history was uneventful. Her chief complaint was the absence of teeth and she sought reconstructive treatment to achieve a full complement of teeth. She was aware that reconstruction was not necessary for normal function and she declined full comprehensive orthodontic treatment.

Because of the patient's restrictions on the use of complex orthodontic appliances, a treatment plan was designed to intrude the maxillary first molars in a speedy and objective manner. The clinical procedures consisted of surgical decortications of compact bone associated with a fixed orthodontic appliance in the upper arch. The patient was informed of the disadvantages and advantages of the selected treatment plan. She agreed to proceed and signed the consent form.

Orthodontic Treatment

Bands with double buccal tubes were cemented in the maxillary second molars and second premolars, and

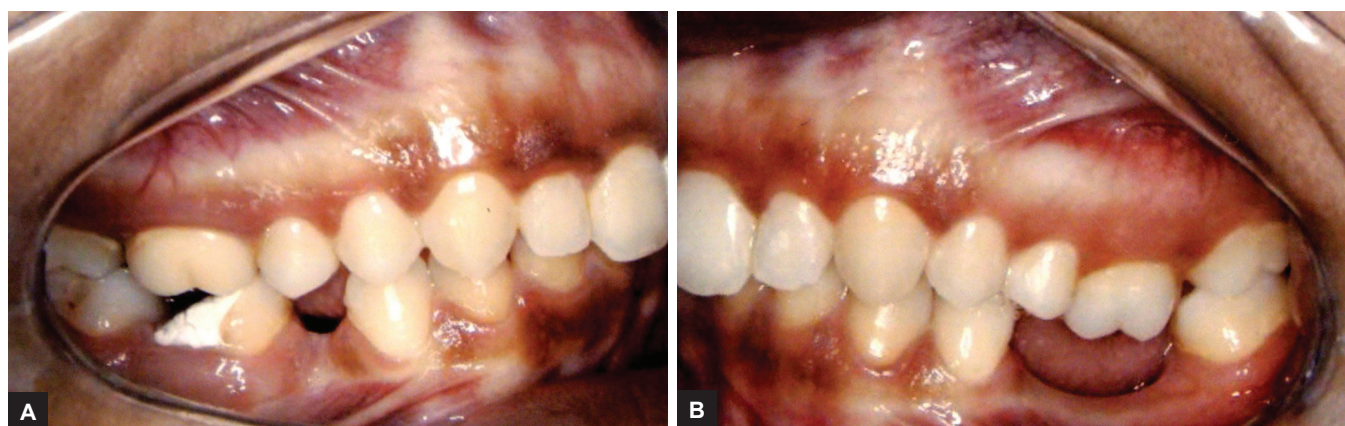
standard edgewise brackets (Dentsply Gac International, Bohemia, New York, USA) were bonded to the remaining teeth. Leveling and alignment procedures were uneventful and mild interproximal reductions were performed to alleviate the existing crowding. Routine archwire sequence bypassing the maxillary first molars was developed until a $0.21 \times 0.25''$ stainless steel archwire was inserted also bypassing the overerupted teeth. One week after surgical decortications, a segmented $0.17 \times 0.25''$ heat-activated archwire (Neosentalloy, Dentsply Gac International, Bohemia, New York, USA) was inserted in the auxiliary slots in the bands of both second premolars and second molars and tied to the brackets of the first molars to initiate intrusion (Figs 2A and B). Five weeks later, the $0.17 \times 0.25''$ wire was replaced by another segmented thermoactivated archwire ($0.18 \times 0.25''$ Neo-Sentalloy; Dentsply Gac International, Bohemia, New York, USA) to conclude the intrusion.

Adequate intrusion of the maxillary first molars was achieved after approximately 4 months of active treatment with the thermoactivated archwires (Figs 3A and B). Clinical observations and cephalometric superimpositions confirmed the intrusion with no undesired movement of the adjacent teeth (Figs 4 and 5).

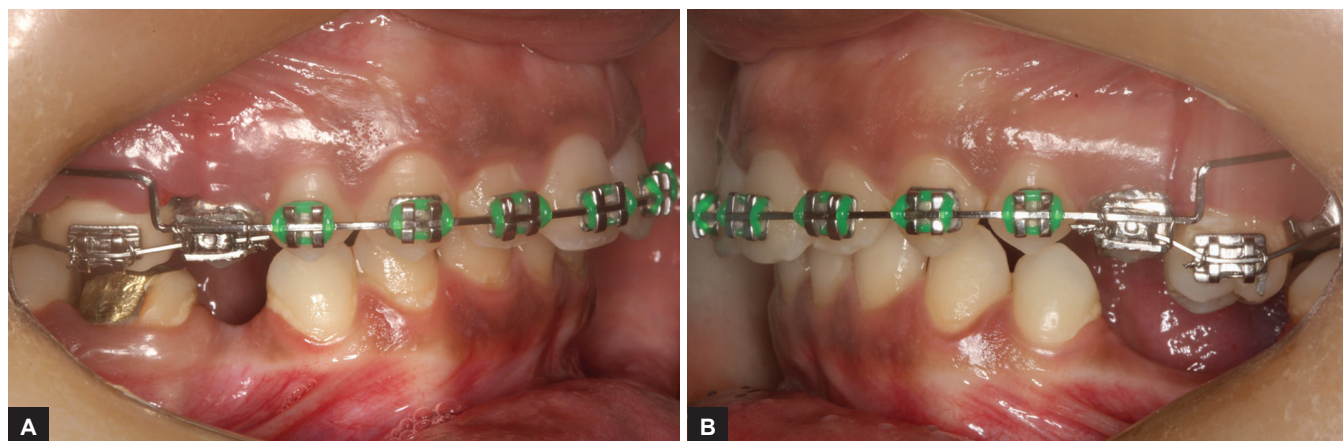
Surgical Procedure

Full-thickness buccolingual gingival flaps were reflected exposing the cortical bone in both palatal and buccal sides of the maxillary first molars, and selective decortication was performed under local anesthesia based on a previously reported protocol.²

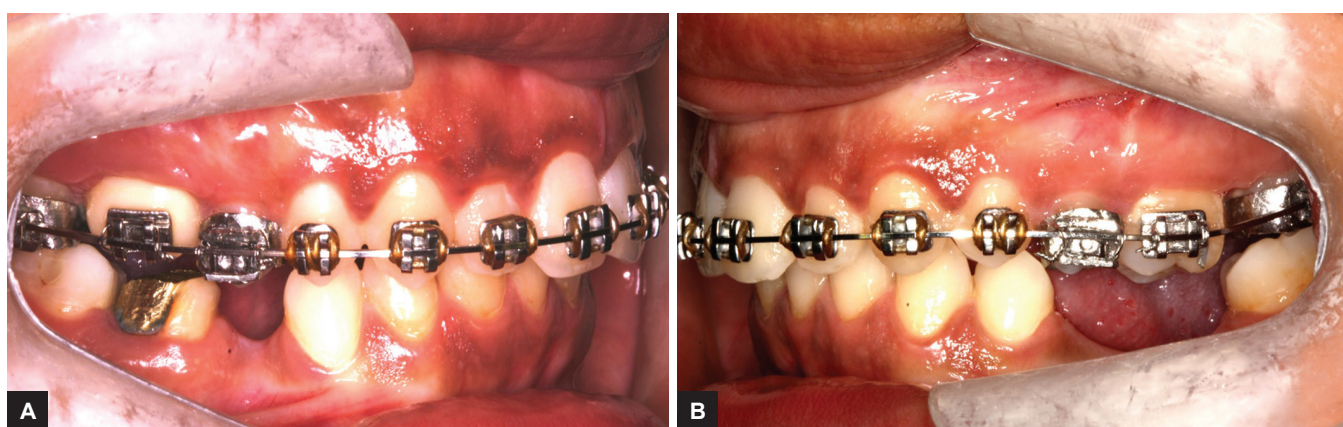
Two vertical bone cuts, mesial and distal to the maxillary first molars, were made extending from 2 mm above the alveolar crest up to approximately 2 mm beyond the root apices and then connected horizontally. Nine small round perforations were made in this area (Figs 6 and 7). The procedure was performed on the palatal and buccal



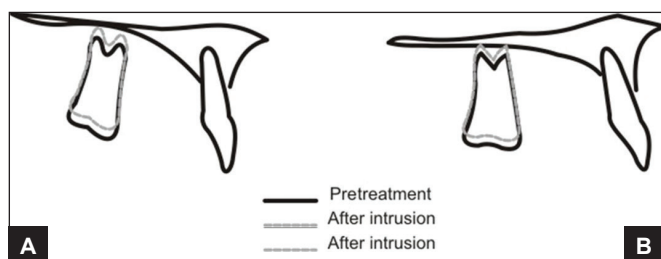
Figs 1A and B: Pretreatment intraoral photographs: (A) Right side, and (B) Left side



Figs 2A and B: One week postcorticotomy and beginning of intrusive force application: (A) Right side, and (B) Left side



Figs 3A and B: End of intrusive phase approximately 4 months postdecortication: (A) Right side, and (B) Left side

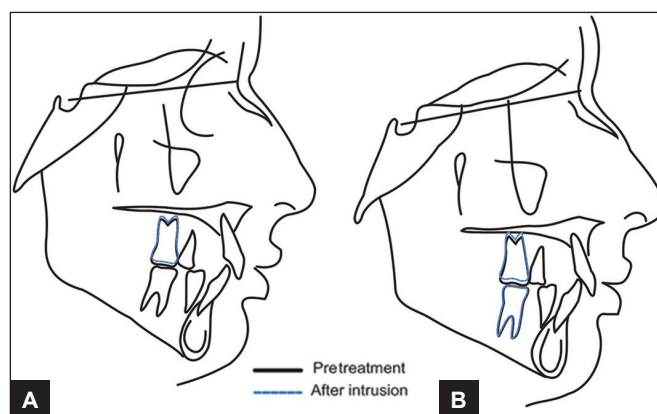


Figs 4A and B: Localized superimpositions showing intrusion of the overerupted molars: (A) Right side superimposition, and (B) Left side superimposition

sides. All bones cuts were made with a 2.0 mm round bur (Meisinger USA LLC, Centennial, Colorado, USA) under continuous and abundant irrigation with cold sterile saline solution. Finally, the flaps were repositioned and sutured. The surgical procedure was well tolerated by the patient and no unusual pain or discomfort was reported.

DISCUSSION

Extruded molars as a result of the loss of teeth in the opposing arch can be a challenge to the restorative dentist when placing an implant or a replacement crown. Several



Figs 5A and B: Total superimpositions showing absence of undesired extrusion on the second premolars and second molars noticed because there were no changes in the patient's overbite and no clockwise rotation of the mandible: (A) Upper molar superimposition, and (B) Upper and lower molar superimposition

clinical options including conventional orthodontic treatment, enamel reduction, endodontic treatment, periodontal surgery, and restoration of the affected tooth can provide a more favorable restorative condition. In conventional orthodontic treatment, the clinician will have to deal with reactive movement of the anchorage

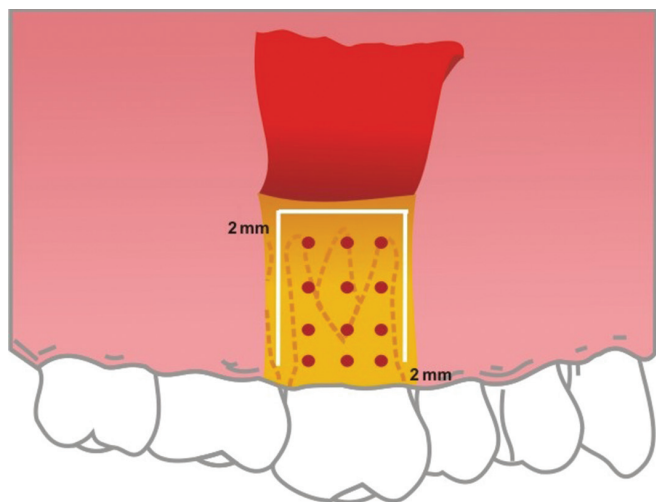


Fig. 6: Desired corticotomy. Vertical and horizontal bone cuts as well as the intended bone perforations can be observed

teeth,^{1,2} and the routine clinical procedures are complex and most possibly unnecessary.

An efficient and balanced force system to intrude a tooth is obtained when a low and continuous force is applied to the center of resistance of that tooth.²² Alveolar bone decortications have been proven to promote rapid tooth movement. Orthodontic movement in decorticated bone takes 60–70% less time than in nondecorticated bone.^{13,19,23} Animal studies^{16,23,24} and clinical reports^{1,2,25,26} have demonstrated the efficiency of corticotomy in facilitating orthodontics. Alveolar bone corticotomy permits faster tooth movement because it reduces the main source of resistance which is encountered in the cortical layer.²⁷ It can be applied to a single tooth or a group of teeth.

Increased bone turnover has been reported in the literature as late as 6 months after bone fracture.²⁸⁻³⁰ The case presented demonstrates that it is possible to initiate successful orthodontic movement 7 days after the decortication procedure and achieve the desired results in shorter treatment times than those obtained with conventional orthodontic mechanics. Recent studies^{2,3,19} have demonstrated that after corticotomy, the total amount of orthodontic movement is approximately two times faster when initiated after the surgical procedure. Recently, Kim et al³¹ reported intrusions and uprighting of molars in short but perhaps not much different time than without decortication. The authors reported using heavy forces and suggested that tooth movement within the alveolar bone framework may explain the treatment time obtained. Differently, in the case presently reported, light and continuous forces were used, which may have contributed to the differences in total treatment time. In addition, the auxiliary tubes welded to the premolar and

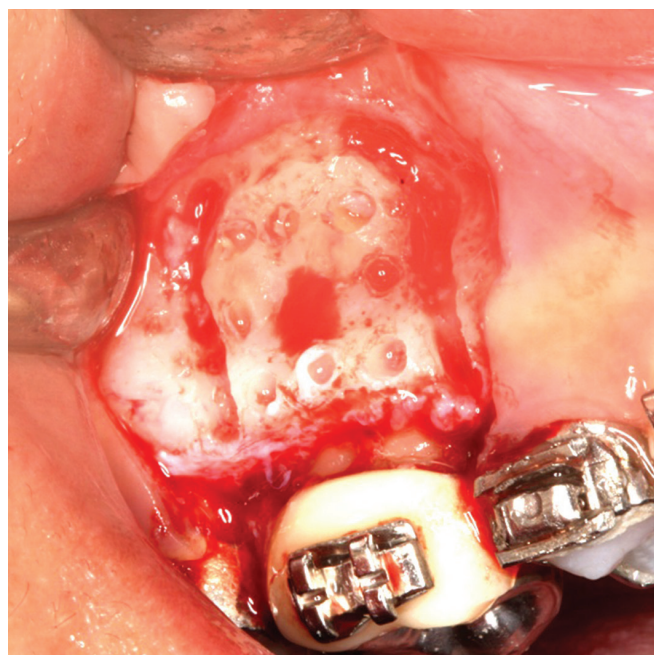


Fig. 7: Surgical procedure

second molar bands represent a low-friction system that allowed free sliding of the heat-activated wires used for intrusion. Such mechanical characteristics may also have contributed to increase the efficiency of the protocol used.

CONCLUSION

Treatment time was short when compared with conventional orthodontic treatment.

This treatment protocol avoided removal of sound tooth structure, endodontic treatment, periodontal surgery for crown lengthening, crown restorations, and placement of temporary anchorage devices.

Based on sound scientific evidence, this patient was successfully treated by a combination of corticotomy and fixed appliances with a low and continuous force released by thermoactivated archwires.

REFERENCES

1. Mostafa YA, Tawfik KM, El-Mangoury NH. Surgical-orthodontic treatment for overerupted maxillary molars. *J Clin Orthod* 1985;19(5):350-351.
2. Oliveira DD, Oliveira BF, Brito HHA, Souza MMG, Medeiros PJ. Selective alveolar corticotomy to intrude overerupted molars. *Am J Orthod Dentofacial Orthop* 2008 Jun;133(6): 902-908.
3. Norton LA, Lopes I. Specific mechanics for abutment uprighting. *Austral Dent J* 1980;25:273-278.
4. Spalding PM, Cohen BD. Orthodontic adjunctive treatment in fixed prosthodontics. *Dent Clin North Am* 1992 Jul;36(3): 607-629.
5. Meldrum RJ. Alterations in upper facial growth of *Macaca mulatta* resulting from high-pull headgear. *Am J Orthod* 1975 Apr;67(4):393-411.

6. Alessandri Bonetti GA, Giunta D. Molar intrusion with removable appliance. *J Clin Orthod* 1996 Aug;30(8):43-47.
7. Woods MG, Nanda RS. Intrusion of posterior teeth with magnets. An experiment in growing baboons. *Angle Orthod* 1988 Apr;58(2):136-150.
8. Enacar A, Pehlivanoglu M, Akcan CA. Molar intrusion with a palatal arch. *J Clin Orthod* 2003 Oct;37(10):557-559.
9. Cheng SJ, Tseng IY, Lee JJ, Kok SH. A prospective study of the risk factors associated with failure of mini-implants used for orthodontic anchorage. *Int J Oral Maxillofacial Implants* 2004 Jan-Feb;19(1):100-106.
10. Liou EJ, Pai BC, Lin JC. Do miniscrews remains stationary under orthodontic forces? *Am J Orthod Dentofacial Orthop* 2004 Jul;126(1):42-47.
11. Fabroni G, Aabed S, Mizzen K, Starr DG. Transalveolar screws and the incidence of dental damage: a prospective study. *Int J Oral Maxillofacial Surg* 2004 Jul;33(5):442-446.
12. Hwang HS, Lee KH. Intrusion of overerupted molars by corticotomy and magnetics. *Am J Orthod Dentofacial Orthop* 2001 Aug;120(2):209-216.
13. Wilcko MW, Wilcko MT, Bouquot JE, Ferguson DJ. Rapid orthodontics with alveolar reshaping: two case reports of decrowding. *Int J Periodontics Restorative Dent* 2001 Feb;21(1):9-19.
14. Yen SL, Gross J, Wang P, Yamashita DD. Closure of a large alveolar cleft by bony transport of a posterior segment using orthodontics wires attached to bone: report of a case. *J Oral Maxillofac Surg* 2001 Jun;59(6):688-691.
15. Yen SL, Yamashita DD, Gross J, Meara JG, Yamazaki K, Kim TH. Combining orthodontic tooth movement with distraction osteogenesis to close cleft spaces and improve maxillary arch form in cleft lip and palate patients. *Am J Orthod Dentofacial Orthop* 2005 Feb;127(2):224-232.
16. Mostafa AY, Salah MM, Mehanni S, ElBokle NN, Heider AM. Comparison of corticotomy-facilitated *vs* standard tooth-movement techniques in dogs with miniscrews as anchorage units. *Am J Orthod Dentofacial Orthop* 2009 Oct;136(4):570-577.
17. Generson RM, Porter JM, Zell A, Stratigos GT. Combined surgical and orthodontic management of anterior open bite using corticotomy. *J Oral Surg* 1978 Mar;36(3):216-219.
18. Suya, H. Corticotomy in orthodontics. Hosl, E.; Baldauf, A., eds. Mechanical and biological basics in orthodontic therapy. Heidelberg, Germany: Huthig Buch Verlag; 1991. p. 207-226.
19. Wilcko MW, Wilcko TM, Fergusson DJ, Bouquot JE. Rapid orthodontic decrowding with alveolar augmentation: case report. *World J Orthod* 2003 Fall;4(3):197-205.
20. Moon CH, Wee JU, Lee HS. Intrusion of overerupted molars by corticotomy and orthodontic skeletal anchorage. *Angle Orthod* 2007 Nov;77(6):1119-1125.
21. Akay MC, Aras A, Günbay T, Akyalçın S, Koyuncue BO. Enhanced effect of combined treatment with corticotomy and skeletal anchorage in open bite correction. *J Oral Maxillofac Surg* 2009 Mar;67(3):563-569.
22. Marcotte, MR. Biomechanics in orthodontics. Philadelphia, PA: BC Decker Inc.; 1990.
23. Sebaoun JD, Kantarci A, Turner JW, Carvalho RS, Van Dyke TE, Fergusson DJ. Modeling of trabecular bone and lamina dura following selective alveolar corticotomies in rats. *J Periodontol* 2008 Sep;79(9):1679-1688.
24. Lino S, Sakoda S, Ito G, Nishimori T, Ikeda T, Miyawaki S. Acceleration of orthodontic tooth movement by alveolar corticotomy in the dog. *Am J Orthod Dentofacial Orthop* 2007 Apr;131(4):448.e1-8.
25. Anholm M, Crites D, Hoff R, Rathburn E. Corticotomy-facilitated orthodontics. *Calif Dent Assoc J* 1986;14(12):7-11.
26. Gantes B, Rathburn E, Anholm M. Effects on the periodontium following corticotomy-facilitated orthodontics. Case report. *J Periodontol* 1990 Apr;61(4):234-238.
27. Köle H. Surgical operation on the alveolar ridge to correct occlusal abnormalities. *Oral Surg Oral Med Oral Pathol* 1959 May;12(5):515-529.
28. Frost HM. The regional acceleratory phenomenon: a review. *Henry Ford Hosp Med J* 1983;31(1):3-9.
29. Frost HM. The biology of fracture healing. An overview for clinicians. Part I. *Clin Orthop Relat Res* 1989 Nov;(248):283-293.
30. Frost HM. The biology of fracture healing: An overview for clinicians. Part II. *Clin Orthop Relat Res* 1989 Nov;(248):294-309.
31. Kim SH, Kook YA, Jeong DM, Lee W, Chung KR, Nelson G. Clinical application of accelerated osteogenic orthodontics and partially osseointegrated mini-implants for minor tooth movement. *Am J Orthod Dentofacial Orthop* 2009 Sep;136(3):431-439.