

RESEARCH ARTICLE

Position of Mental Foramen among Saudi Population: A Radiographic Study

¹Kamran Bokhari, ²Abdul A Shahrani, ³Abdel B Mustafa, ⁴Yhya Hdban, ⁵Mohammad Saleh, ⁶Abdullah Mofareh

ABSTRACT

The mental foramen is defined as the entire funnel-like opening in the lateral surface of the mandible at the terminus of the mental canal. The location of the mental foramen is of high significance while giving nerve block technique for adequate pain control to perform surgical procedures. Many studies have been conducted across the world, and a wide range of literature has been published on this topic. This study aims to determine the position of the mental foramen in southern Saudi Arabian population. This would act as a guide while anesthetizing the mental nerve and also in preserving the nerve while performing surgical procedures in this region.

Keywords: Inferior alveolar nerve, Mental foramen, Surgery.

How to cite this article: Bokhari K, Shahrani AA, Mustafa AB, Hdban Y, Saleh M, Mofareh A. Position of Mental Foramen among Saudi Population: A Radiographic Study. *Int J Experiment Dent Sci* 2016;5(2):109-112.

Source of support: Nil

Conflict of interest: None

INTRODUCTION

The mental foramen is defined as the entire funnel-like opening in the lateral surface of the mandible at the terminus of the mental canal.¹ As a branch of inferior alveolar nerve, the mental nerve exits from the mental foramen and provides sensory innervation to the lower lip, gingiva, and the skin over the mental region. During surgical procedures, such as mandibular osteotomies, surgical removal of impacted teeth, apicectomy, enucleation of cysts, and excision of tumors, the mental nerve can get damaged, causing functional and psychosocial problems over the region where it innervates. Compression injury of the mental nerve can also occur while excessive stretching of

the nerve during surgical procedures. Iatrogenic damage of the nerve can occur during implant placement.

The average size of the foramen is 4.6 mm horizontally and 3.4 mm vertically on the lateral surface of the mandible as mentioned by Ngeow and Yuzawati¹ in their study. Amorim et al² stated that the orientation and position of the mental foramen is very important in anesthetic nerve block prior to clinical procedures. In their study involving dried skull, they also reported variation in the location of the mental foramen. Rupesh et al³ conducted a study involving panoramic radiographs to determine the position of the mental foramen among Asian Indian population and concluded that the most common position of the mental foramen was between the 1st and 2nd premolars followed by being apical to the 2nd premolar. They also suggested that panoramic radiograph is a better diagnostic modality than computed tomography (CT) scan in determining the position of the mental foramen as it exposes the patient to a significantly lower radiation exposure. Al-Juboori et al⁴ conducted a study among Malaysian population to determine the position of the mental foramen involving 600 OPG's. The most frequent position of the mental foramen was between the 1st and 2nd premolars. Ukoha et al⁵ conducted a study among south-eastern Nigeria population to study the position, shape, and direction of the opening of the mental foramen. Their study involved 66 dry adult human mandibles. They concluded that the most frequent position of the mental foramen was in line with the longitudinal axis of the 2nd premolar (58.33%). Al-Khateeb et al⁶ conducted a study involving Saudi Arabian population. Their study involved 404 dentate mandibles, and they concluded that the most frequent position of the mental foramen was between the 1st and 2nd premolars. Al Jasser and Nwoku⁷ conducted a radiographic study to determine the most frequent position of the mental foramen involving 414 panoramic radiographs and concluded that the most frequent position of the mental foramen was in line with the 2nd premolar.

AIMS AND OBJECTIVES

- To assess the most frequent position of the mental foramen (along the horizontal and vertical axes) among southern Saudi Arabian population.

^{1,2}Assistant Professor, ³Associate Professor and Head, ⁴Resident
^{5,6}Intern

^{1,3-6}Department of Oral and Maxillofacial Surgery, College of Dentistry, King Khalid University, Abha, Asir, Kingdom of Saudi Arabia

²Department of Orthodontics, College of Dentistry, King Khalid University, Abha, Asir, Kingdom of Saudi Arabia

Corresponding Author: Kamran Bokhari, Assistant Professor Department of Oral and Maxillofacial Surgery, College of Dentistry, King Khalid University, Abha Asir, Kingdom of Saudi Arabia, Phone: +966535441946, e-mail: ksayed@kku.edu.sa

- To compare the difference in position of the mental foramen on the right and left sides.
- To highlight the difference in the position of the mental foramen on the right and left sides and the variation in position with gender and age.

MATERIALS AND METHODS

This was a retrospective study that involved the analysis of orthopantomograms (OPG) over a period of 5 years (2009–2014). The total number of radiographs analyzed were 900. A criterion was established to identify and record the position of the mental foramen. The data were decoded and entered into an excel spreadsheet. Descriptive analysis of the data was done. Data were retrieved from the radiograph software of the institution after ethical approval. Every OPG was assessed by a minimum of two investigators. Results were displayed as graphs.

The position of the mental foramen has been classified into four types (according to the position on the horizontal axis):

1. Position I: Mesial to 1st premolar
2. Position II: In between the 1st and 2nd premolars
3. Position III: Distal to the 2nd premolar
4. Position IV: Cannot be assessed radiographically

The position of the level of the mental foramen on the vertical axis is divided into the following types:

- Inferior to the apex of the 1st premolar
- Inferior to the apex of the 2nd premolar
- At the level of the apex of the 1st premolar
- At the level of the apex of the 2nd premolar
- Superior to the apex of the 1st premolar
- Superior to the apex of the 2nd premolar.

INCLUSION CRITERIA

- All patients in the age group 25 to 65 years
- Patients with no significant deformity and pathology

- Patients with full complement of teeth anterior to the 2nd molar

EXCLUSION CRITERIA

- Orthopantomograms without clarity
- Patients who underwent orthodontic treatment
- Patients with crowded dentition
- Patients with missing teeth anterior to the 1st molar
- Patients having benign or malignant pathologies (cysts, tumors, infection, and granuloma)
- Patients with plate fixation following any surgical procedure in the mandible.

RESULTS

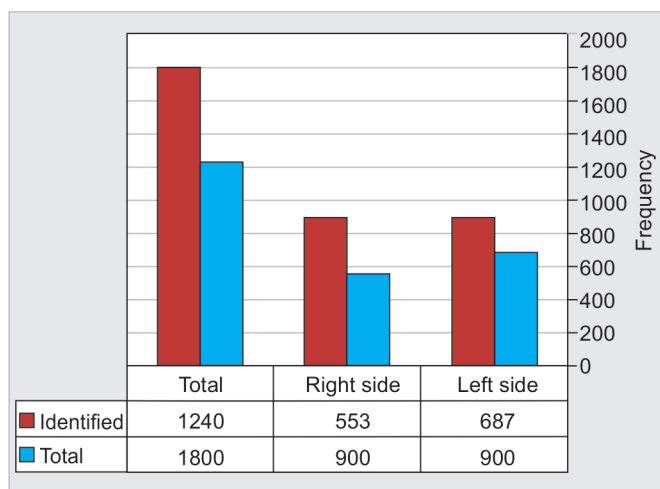
A total of 900 OPGs were assessed. Radiologically, the mental foramen could be located only in 1,240 (68.8%) out of the 1,800 sides assessed (in 900 OPGs). A total of 687 mental foramen were assessed on the left side and the remaining 553 on the right side (Graph 1).

As shown in Graphs 2 and 3, the highest incidence of mental foramen along the horizontal axis was in between the two premolars on the right and left sides.

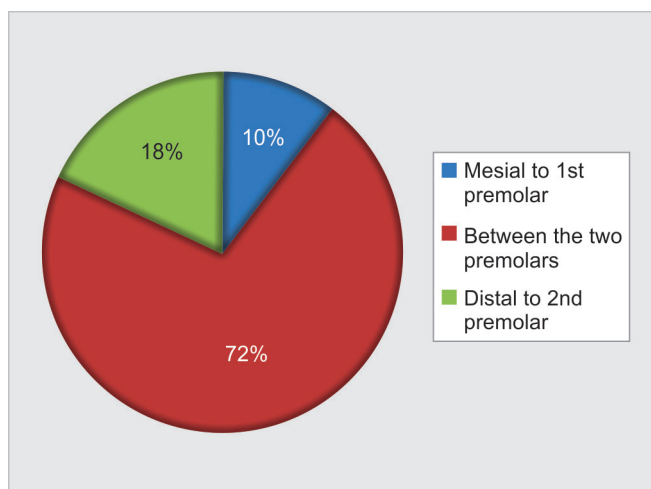
Graph 4 shows the position of the mental foramen along the vertical axis. Majority of the patients had the mental foramen inferior to the apex of the 1st premolar (both on the right and left sides).

DISCUSSION

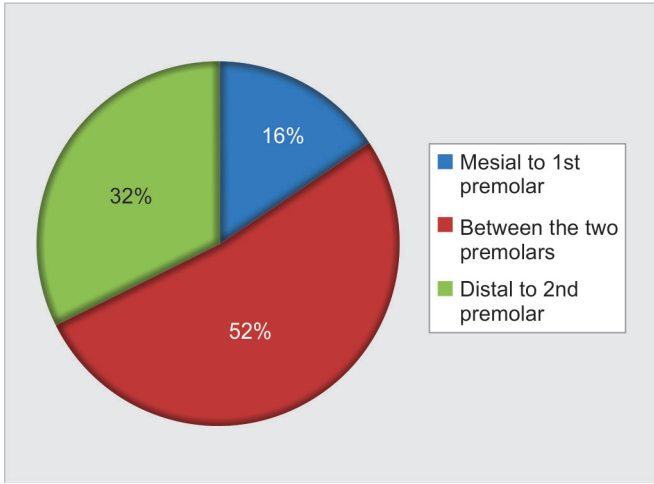
The mental foramen is an important anatomical structure located on the lateral surface of the mandible.⁸ As the mental neurovascular bundle comes out of the mental foramen to innervate the buccal gingiva anterior to the premolar teeth and supplies the lower lip, the surgeon has to be careful in planning the incision and reflection of mucoperiosteal flap in this region. Inadvertent trauma



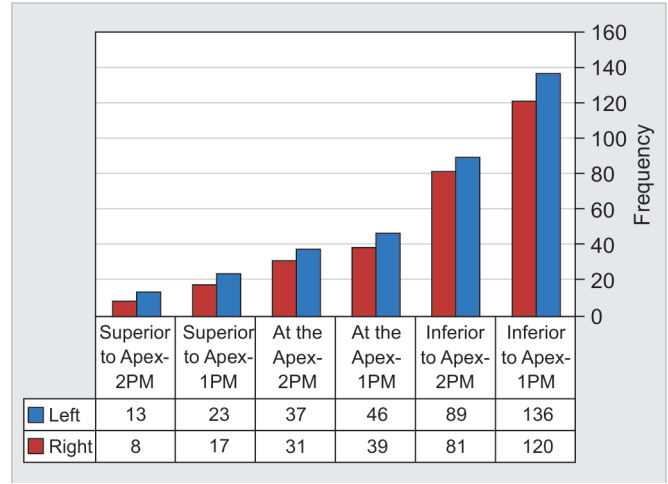
Graph 1: Total number of mental foramen and its distribution



Graph 2: Position of the mental foramen on the left side – horizontal axis



Graph 3: Position of the mental foramen on the right side – horizontal axis



Graph 4: Position of the mental foramen along the vertical axis

to the mental neurovascular bundle can cause a wide range of neurosensory deficit ranging from neuropraxia to neurotemesis. This makes it necessary to have a precise knowledge of the anatomy of the mental foramen. Mental foramen in early childhood lies near the lower border. After eruption of permanent dentition, the mental foramen lies higher, halfway between the upper and lower border.⁴ The mental foramen appears as a radiolucent area in the lower premolar region, sometimes overlapping an apex of a premolar.⁹ Apart from a wide range of surgical procedures performed in this region (extraction, periapical surgery, cystic enucleation, orthognathic surgical procedures), the determination of the position of the mental foramen is essential for the differential diagnosis of lesions in this region.

The most prominent position for the mental foramen is in between the two premolars. This is in accordance with most of the studies conducted elsewhere in different populations. Fishel et al⁹ in 1976 conducted a similar study involving 1,000 full-mouth intraoral radiographs in Jerusalem and found the most prominent position of the mental foramen to be in between the two premolars. Kieser et al¹⁰ in 2002 performed a study to assess the patterns of emergence of human mental nerve involving 328 skulls. They stated that the emergence of mental nerve is genetically rather than functionally determined. Amorim et al² in 2008 stated that the position of the mental foramen varies in different ethnic groups. They assessed the position of the mental foramen in 170 Brazilian adult dry skulls, which included both edentulous and dentate skulls. The most prominent position of the mental foramen in their study was in the long axes of the 2nd premolar as against our study, where the most prominent position is inferior to the apex of the 1st premolar, as shown in Graph 4. Moiseiwitsch

and Hill¹¹ in 1997 conducted a study in North American white population involving regional dissections in 105 human cadavers. Results of their study were similar to that of the present study with regard to the position of the mental foramen; that is, the most prominent position of the mental foramen is in between the two premolars. Neo¹² in 1989 stated that the most frequent location does not conform to the position cited in many anatomy, surgery, and dental anesthesia texts as being below and between the apices of the lower premolars. We feel that this variation is due to the difference in the position of the mental foramen in different ethnic races, as also stated by Budhiraja et al.¹³ As such there is a need to conduct studies involving different races to determine the position of the mental foramen. Though the entire body of the mandible can be viewed on a panoramic radiograph, it is sometimes difficult to view the mental foramen on panoramic radiographs. This is the reason that though 1,800 sides were assessed in our present study, only on 1,240 sides the mental foramen was visible/assessed. Most of the literature stated that mental foramen location is important to give mental nerve block anesthesia. On the contrary, we are of the opinion that even if local anesthetic solution is deposited at some distance from the mental foramen, still the nerve block would act by diffusion of the anesthetic agent. We are of the opinion that localization of the mental foramen is more important to use it as a guide while performing osteotomy cuts in orthognathic surgical procedures and in periapical surgeries to avoid neurosensory disturbances.

CONCLUSION

- The most prominent position of the mental foramen is in between the two premolars in the horizontal axis and apical to the 1st premolar in the vertical axis.

- Though panoramic radiographs are a standard means to assess the position of the mental foramen, it is better to conduct studies involving human died skulls.
- The position of the mental foramen varies according to ethnic group.
- An assessment of the mental foramen is essential to avoid neurosensory disturbances while performing orthognathic and periapical surgical procedures.

REFERENCES

1. Ngeow WC, Yuzawati Y. The location of the mental foramen in a selected Malay population. *J Oral Sci* 2003 Sep;45(3):171-175.
2. Amorim MM, Prado FB, Borini CB, Bittar TO, Volpato MC, Groppo FC, Caria PHF. The mental foramen position in dentate and edentulous Brazilian's mandible. *Int J Morphol* 2008;26(4):981-987.
3. Rupesh S, Winnier JJ, John SA, Joy T, Rao AP, Reddy V. Radiographic study of the location of mental foramen in a randomly selected Asian Indian population on digital panoramic radiographs. *J Med Sci* 2011;11(2):90-95.
4. Al-Juboori MJ, Al-Wakeel HA, Yun CM, Wen FS. Location of mental foramen among Malaysia population: retrospective study by using orthopantomogram. *World J Med Sci Res* 2013;1(5):85-90.
5. Ukoha UU, Umeasalugo KE, Ofoego UC, Ejimofor OC, Nzeako HC, Edokwe CG. Position, shape and direction of the mental foramen in mandible in South-Eastern Nigeria. *IJBR* 2013;4(9):499-503.
6. Al-Khateeb TL, Odukoya O, El-Hadidy MA. Panoramic radiographic study of mental foramen locations in Saudi Arabians. *Afr Dent J* 1994;8:16-19.
7. Al Jasser NM, Nwoku AL. Radiographic study of the mental foramen in a selected Saudi population. *Dentomaxillofac Radiol* 1998 Nov;27(6):341-343.
8. Philips JL, Weller RN, Kulild JC. The mental foramen: Part I. Size, orientation, and positional relationship to the mandibular second premolar. *J Endod* 1990 May;16(5):221-223.
9. Fishel D, Buchner A, Hershkowitz A, Kaffe I. Roentgenologic study of the mental foramen. *Oral Surg Oral Med Oral Pathol* 1976 May;41(5):682-686.
10. Kieser J, Kuzmanovic D, Payne A, Dennison J, Herbison P. Patterns of emergence of the human mental nerve. *Arch Oral Biol* 2002 Oct;47(10):743-747.
11. Moiseiwitsch JRD, Hill C. Position of the mental foramen in a North American, white population. *Oral Surg Oral Med Oral Pathol Oral Radiol Endod* 1998 Apr;85(4):457-460.
12. Neo J. The position of the mental foramen in Singaporean Malays and Indians. *Anesth Prog* 1989 Nov-Dec;36(6):276-278.
13. Budhiraja V, Rastogi R, Lalwani R, Prabhat G, Bose SC. Study of position, shape, and size of mental foramen utilizing various parameters in dry adult human mandibles from North India. *ISRN Anat* 2012 Dec 17;2013:961429. Available from: <http://dx.doi.org/10.5402/2013/961429>.