

CASE REPORT

Concealment of Amputation: Silicone Finger Prosthesis

¹Brajendra S Tomar, ²GS Chandu, ³Shubhra Singh, ⁴Makrand Sapat, ⁵Monika Khatri, ⁶Priyanka Jain

ABSTRACT

Hand deformities affects function and esthetics. Moreover, for the majority of patients, the loss of a finger can lead to psychological problems. This report describes the fabrication of a silicone finger prosthesis for a patient after an accident. The finger prosthesis was retained by a vacuum effect on the stump. The room temperature vulcanizing (RTV) silicone material was used to provide function and esthetics. The finger prosthesis offered psychological, functional, and rehabilitative advantages for the patient.

Keywords: Amputee, Digit prosthesis, Limb prosthesis, Silicone finger prosthesis.

How to cite this article: Tomar BS, Chandu GS, Singh S, Sapat M, Khatri M, Jain P. Concealment of Amputation: Silicone Finger Prosthesis. *Int J Experiment Dent Sci* 2016;5(2):146-150.

Source of support: Nil

Conflict of interest: None

INTRODUCTION

Any kind of deformity, facial or elsewhere, may cause psychological and emotional disturbance to the patient as well as social annihilation. Traumatic amputation of a finger causes serious damage to the function of the hand. Currently, many injuries and traumatic amputations of fingers can be rescued by microsurgery through reimplantation. However, in some cases, reconstruction is either not advisable or partially successful.¹

The loss of a finger produces significant functional deficiencies. In addition to immediate loss of grasp strength and security, finger absence may also cause marked psychological trauma. Although, the intensity of

this trauma varies among individuals, the psychological impact is not related to the magnitude of amputation. Despite the advances in microsurgical techniques.²⁻⁴

Several microsurgical techniques, such as toe-foot transfer, foot lengthening procedure, and use of osteo-cutaneous flaps may offer opportunities to reconstruct the lost or missing phalanges.⁵ In case of any contraindications or failure of these surgical methods, esthetic finger prosthesis is an option for the restoration of the handicap.⁶ Prosthesis refers to artificial replacement of an absent part of the human body.

A prosthesis can often restore a “near-normal function” in the distal phalangeal amputation.⁷ Finger prosthesis requires an optimum retention for functions, such as, grasping, carrying, and holding.⁸

The traditional method of prosthesis is replacing the lost finger by an artificial digit. The artificial digit is made of a silicone elastomer (chemical name: polysiloxane).⁹

These silicones can be rendered to match the skin color of the patient and give a more lifelike appearance. Most of silicones used for this purpose are room temperature vulcanizing (RTV) silicones as they offer chemical inertness, flexibility, and elasticity.¹⁰

CASE REPORT

A 48-year-old male patient reported to the Department of Prosthodontics, Crown and Bridge and Implantology, Rishiraj College of Dental Sciences & Research Center, Bhopal, with the complaint of a partially missing finger. The patient revealed a history of having lost the digit in a traumatic injury caused by a road traffic accident. A complete examination of the hand revealed a residual stump terminating in the 3rd phalangeal region, light brown in color on the little finger of the left hand measuring approximately 1 cm.

The area around the residual stump was keratinized without any sign of inflammation (Figs 1 and 2). A treatment plan was formulated to replace the finger with silicone prosthesis. As a part of protocol and to ensure the patient’s willingness and cooperation, an informed consent was signed before beginning the treatment.

PROCEDURE

A preliminary impression was made with irreversible hydrocolloid impression material (Algitek, Dental Product of India (DPI) Pvt, Ltd, India) and supported with type I

^{1,3-6}Postgraduate Student, ²Professor and Head

^{1,2}Department of Prosthodontics, Rishiraj College of Dental Sciences & Research Centre, Bhopal, Madhya Pradesh, India

³Department of Periodontology, Rishiraj College of Dental Sciences & Research Centre, Bhopal, Madhya Pradesh, India

⁴Department of Prosthodontics, Rungta College of Dental Sciences and Research, Bhilai, Chhattisgarh, India

^{5,6}Department of Prosthodontics, Hitkarini Dental College & Hospital, Jabalpur, Madhya Pradesh, India

Corresponding Author: Brajendra S Tomar, Postgraduate Student, Department of Prosthodontics, Rishiraj College of Dental Sciences & Research Centre, Bhopal, Madhya Pradesh, India
Phone: +918269304518, e-mail: dr.bjtomar@gmail.com

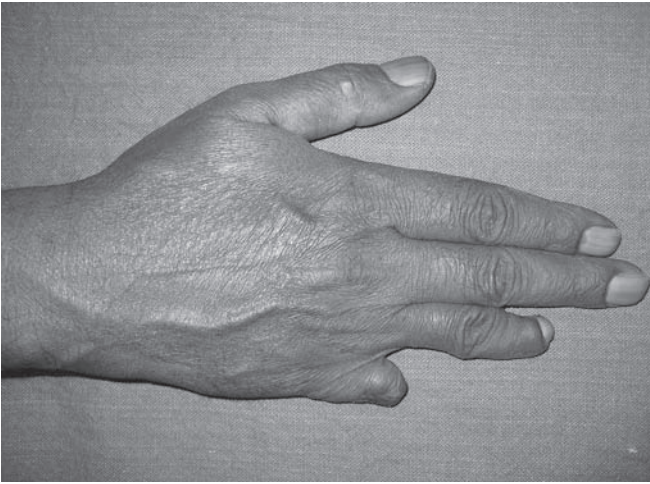


Fig. 1: Preoperative dorsal

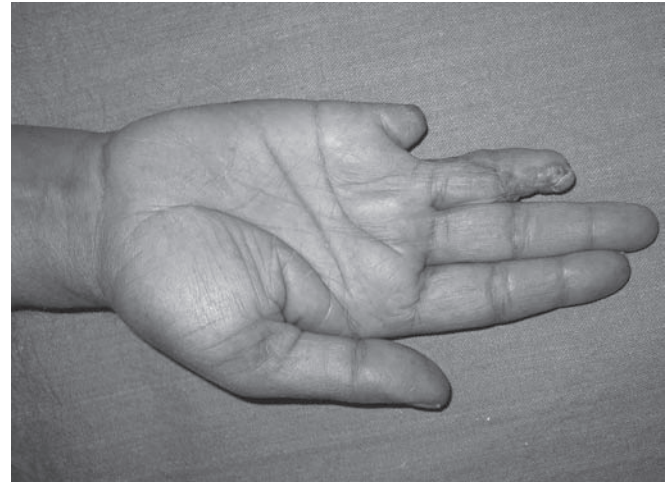


Fig. 2: Preoperative ventral

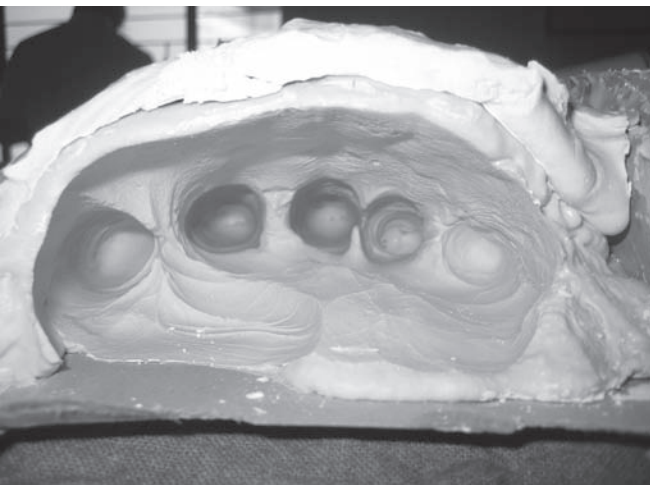


Fig. 3: Impression with irreversible hydrocolloid

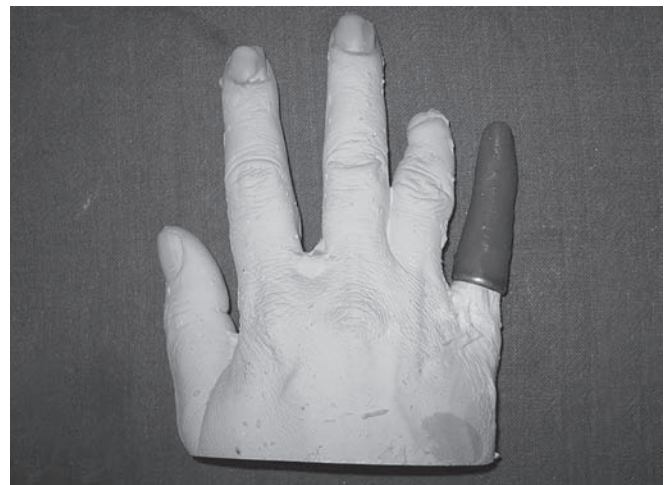

Fig. 4: Wax-up of prosthesis

dental plaster, orthodontic wire was used to lock the plaster with alginate, and the patient was asked to withdraw his hand slowly to avoid tearing of impression (Fig. 3).

Impression was poured in type III dental stone (Dentstone, Neelkanths Health care Products, India). Over the preliminary cast, the wax-up of little finger of the desired shape and size was properly carved and finished to mimic the missing little finger slightly over the base of the remaining finger (Fig. 4).

A brass ring was used to support the wax pattern of the finger prosthesis, and the same ring was later used in order to retain the silicone finger prosthesis.

Autocured tooth-colored acrylic was used to prepare nail of the finger and the nail was attached to the waxed-up finger prosthesis. Finished waxed-up was tried no need to wright patient's hand. After satisfactory try in, wax-up was reseated on working model (Fig. 5).

Flasking and dewaxing were done in such a way to get the demarcation of the ventral and dorsal surface of the waxed-up finger (Fig. 6).

Then, the RTV silicone was mixed and shade matching (Figs 7 and 8) was done separately with the dorsal and ventral surface with intrinsic silicone stains to mimic the patient's adjacent fingers, and then the mixed material is packed separately for ventral and dorsal surface (Fig. 9) into the flask and allowed to set. After an overnight curing at room temperature and a short curing cycle at an elevated temperature of 74°C inside the hot-water bath for 3 hours, the mold was allowed to return to room temperature. The RTV silicone finger prosthesis was then retrieved from the flask (Fig. 10). Finishing and polishing was done with silicone trimming wheels.

The patient was advised to insert the prosthesis by placing by slight pressure with ring (Figs 11 and 12). The patient readily adapted to the prosthesis and was satisfied with the result. The follow-up for the prosthesis was done and checked for adaptation and esthetics at each recall visit every month. Furthermore, instructions were given to keep the prosthesis in water during night to prevent warpage of the prosthesis.

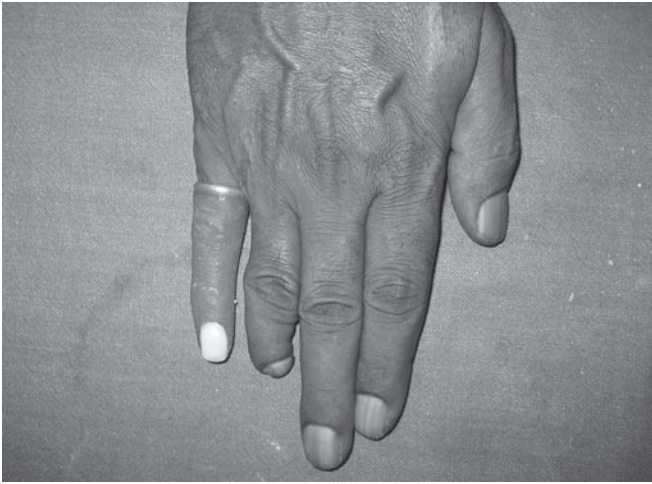

Fig. 5: Try in




Fig. 6: Flasking and processing

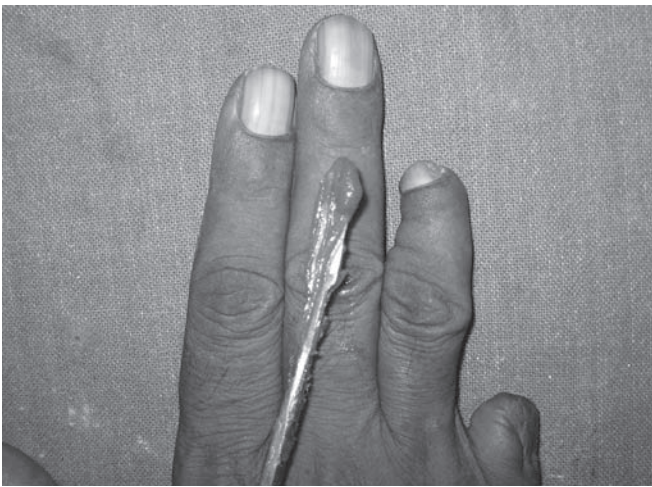

Fig. 7: Shade-matching dorsal

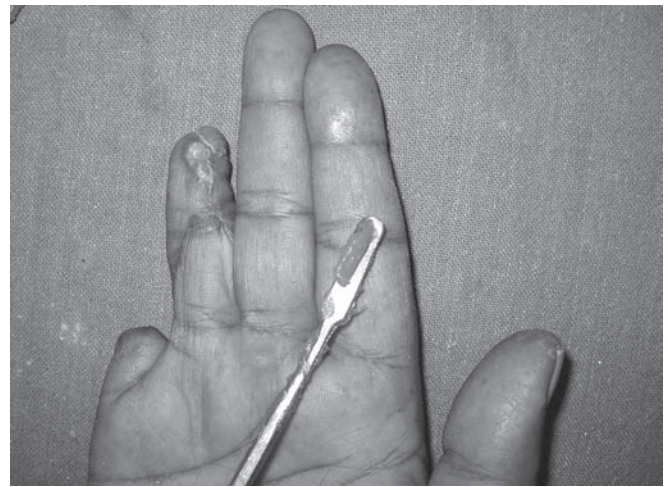

Fig. 8: Shade-matching ventral



Fig. 9: Packing of RTV silicone

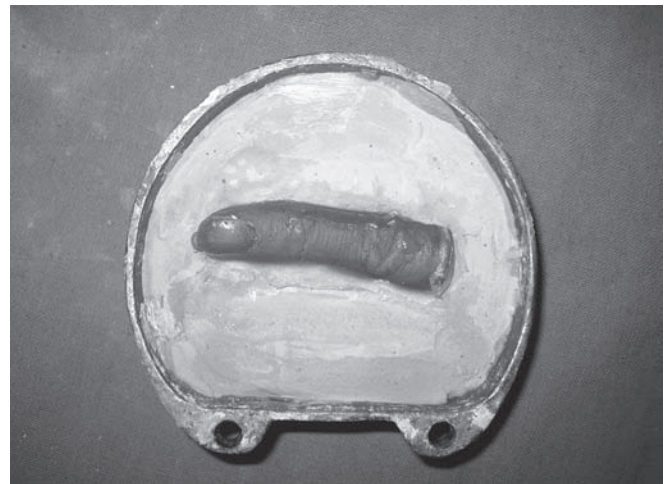


Fig. 10: Cured prosthesis

DISCUSSION

The loss of a finger has both functional and psychological consequences. Even if the stump is adequate for daily functions, poor appearance remains the main concern

for the patient. Beasley (1987) has noted that individuals who keep their hands hidden inside pockets due to embarrassment over appearance are as functionally disabled as a forequarter amputee.¹¹

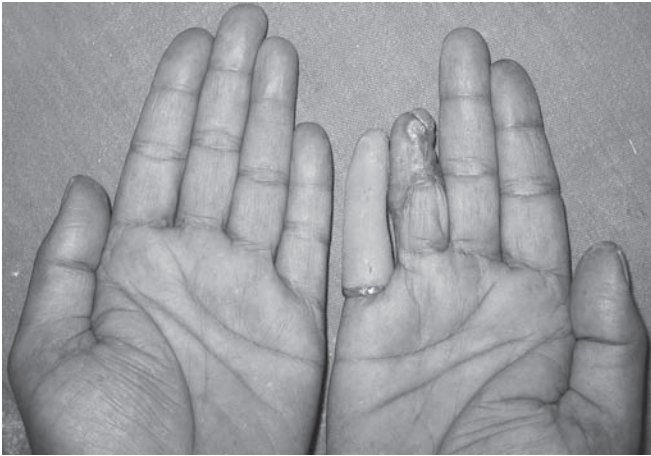

Fig. 11: Postoperative ventral

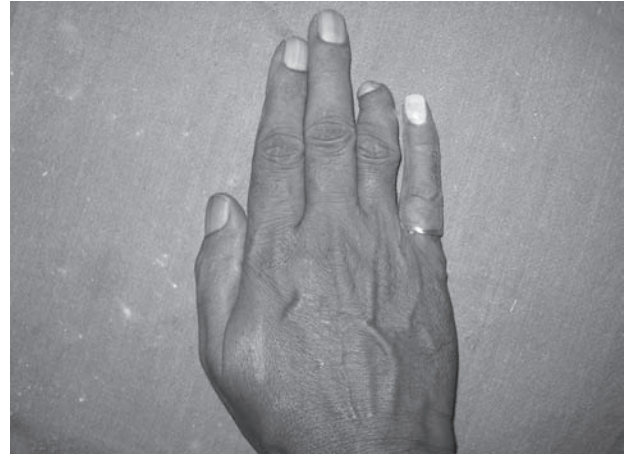

Fig. 12: Postoperative dorsal

The acrylic resin and silicone are the most common materials used for rehabilitation. Although resin can be easily characterized and presents great durability, it is a very hard material and uncomfortable for the patient. On the contrary, silicone has texture and flexibility similar to the skin, provides a more comfortable prosthesis, and presents better capacity for skin-prosthesis linkage. However, this material is more difficult to pigment and degrades due to color instability when exposed to ultraviolet rays.¹²

For the determination of functional capability of the prosthesis, the level of amputation and length of stump preserved were important. It is important to preserve the proximal interphalangeal joint, because mobility of the finger will not be restricted to the metacarpophalangeal joint.

Retention is the primary determinant factor for the success of prosthetic restoration in any part of the body. It is important for esthetics, function, and comfort, thereby improving the patient's quality of life. Finger prostheses are retained by a vacuum effect on the stump.^{12,13} The stump of the amputated finger should be minimally 1.5 cm in length to fit the standard finger prosthesis.¹³ To improve the appearance and aid retention on short stumps, patients can wear a ring at the junction between the prosthesis and stump.¹²

Over time, various materials have been used and have been developed further. Wood, leather, polyurethane, and polyvinyl chloride (PVC) have been used to produce esthetic prosthesis, but silicone rubber has proved to be the most promising in achieving the desired lifelike effects.¹⁴ The acceptance of prosthesis has been much higher with the use of custom restoration using silicone elastomer. Silicone finger restorations may have additional functional benefits. Many traumatic amputees experience painful hypersensitivity at the termination of finger remnants. The gentle, constant pressure of

elastomer prosthesis can help desensitize and protect the injured tip. A lubricant should be used to lubricate the skin to facilitate donning and doffing of the prosthesis.¹⁵

CONCLUSION

Dentistry is varying with induction of modern science to practice dentistry.¹⁶

This case report highlighted the fabrication of a silicone finger prosthesis for amputated little finger. This finger prosthesis consists of a metal ring, which was attached at the try in stage. This acts as a retentive aid for the prosthesis, and it hides the demarcating line between prosthesis and remaining structure. The patient's amputated finger was restored and rehabilitated by using simple, economical yet satisfactory means and materials. It's now 6 months after the insertion of prosthesis, and the patient is quite satisfied with the prosthesis and regular recall protocol maintained.

REFERENCES

1. Wilson RL, Carter-Wilson MS. Rehabilitation after amputations in the hand. *Orthop Clin North Am* 1983 Oct;14(4): 851-872.
2. Bickel KD, Dosanjh A. Fingertip reconstruction. *J Hand Surg Am* 2008 Oct;33(8):1417-1419.
3. Hattori Y, Doi K, Sakamoto S, Yamasaki H, Wahegaonkar A, Addosooki A. Fingertip replantation. *J Hand Surg Am* 2007 Apr;32(4):548-555.
4. Shi D, Qi J, Li D, Zhu L, Jin W, Cai D. Fingertip replantation at or beyond the nail base in children. *Microsurgery* 2010 Jul;30(5):380-385.
5. Doppen P, Solomons M, Kritzing S. Osseointegrated finger prostheses. *J Hand Surg Eur* 2009 Feb;34(1):29-34.
6. Cervelli V, Bottini DJ, Arpino A, Grimaldi M, Rogliani M, Gentile P. Bone anchored implant in cosmetic finger reconstruction. *Ann Chir Plast Esthet* 2008 Aug;53(4):365-367.
7. Michael JW, Buckner H. Options for finger prostheses. *J Prosthet Orthot* 1994;6(1):10-19.

8. Pereira BP, Kour AK, Leow EL, Pho RW. Benefits and use of digital prostheses. *J Hand Surg Am* 1996 Mar;21(2): 222-228.
9. Aydin C, Karakoca S, Yilmaz H. Implant-retained digital prostheses with custom-designed attachments: A clinical report. *Journal of Prosthetic Dentistry* 2007;97:191-195.
10. Kanter JC. The use of RTV silicones in maxillofacial prosthetics. *J Prosthet Dent* 1970 Dec;24(6):646-653.
11. Beasley RJ. General considerations in managing upper-limb amputations. *Orthop Clinics of North Amer* 1981;12(4): 743-749.
12. Gary JJ, Huget EF, Powell LD. Accelerated colour change in a maxillofacial elastomer with and without pigmentation. *J Prosthet Dent* 2001 Jun;85(6):614-620.
13. Pilley MJ, Quinton DN. Digital prostheses for single finger amputations. *J Hand Surg Br* 1999 Oct;24(5):539-541.
14. McKinstry RE. *Fundamentals of facial prosthetics*. Arlington (TX): ABI Professional Publications; 1995.
15. Venkataswamy R. *Aesthetic prosthesis in hand injuries surgery of the injured hand*. New York (NY): McGraw-Hill; 2010.
16. Saini R. Ozone therapy in dentistry: a strategic review. *J Nat Sc Biol Med* 2011; 2:151-153.