

## CASE REPORT

# A Rare Case of Radicular Dens in Dente diagnosed by Clinical, Radiographic, Tomographic, and Histopathological Examinations

<sup>1</sup>Ana PD Moreno, <sup>2</sup>Fabrcio K de Carvalho, <sup>3</sup>Alexandra M de Queiroz, <sup>4</sup>Jorge E León, <sup>5</sup>Eduardo P Zanella, <sup>6</sup>Andiara De Rossi

## ABSTRACT

Dens invaginatus is a dental anomaly caused by an invagination of enamel that affects in most of the cases the crown of the tooth. The treatment depends on the degree of invagination and morphological involvement. This report describes a dental anomaly affecting the permanent lower lateral incisor of a 13-year-old patient, which resulted in swelling, pain, and dental impaction. The initial radiographic examination suggested a gemination, a fusion with a supernumerary tooth or a dens invaginatus extending to the root. For more accurate diagnosis and treatment plan of this anomaly, computed tomography scan was performed, which revealed the presence of enamel in the root. Due to pain and the impossibility of performing an orthodontic traction, the treatment of choice in this case was dental extraction. The final diagnosis was confirmed by histopathological examination and revealed the rare occurrence of a radicular dens invaginatus.

**Keywords:** Cone beam computed tomography, Dens in dente, Tooth abnormalities.

**How to cite this article:** Moreno APD, de Carvalho FK, de Queiroz AM, León JE, Zanella EP, De Rossi A. A Rare Case of Radicular Dens in Dente diagnosed by Clinical, Radiographic, Tomographic, and Histopathological Examinations. *Int J Experiment Dent Sci* 2017;6(1):39-43.

**Source of support:** Nil

**Conflict of interest:** None

## INTRODUCTION

Dens invaginatus is a developmental anomaly that results from an invagination of enamel organ into the dental papilla before tooth mineralization. Also known as dens in dente, this malformation is more common in permanent dentition, mainly in maxillary lateral incisors,

with prevalence ranging from 0.04 to 10% and a female predilection of 3:1.<sup>1,2</sup>

The multiple crown and root morphological manifestations of dens invaginatus are classified by Oehlers<sup>3</sup> into three types. In type I, the invagination within the crown does not extend beyond the cemento-enamel junction, in type II, the invagination extends apically beyond the cemento-enamel junction, and in type III, the invagination extends beyond the cemento-enamel junction.<sup>3,4</sup> A rare variation of type III, classified as radicular dens invaginatus or dens invaginatus type IIIb, invaginates into the root connecting with the periodontal ligament, outlined usually by enamel tissue and in rare cases by cementum.<sup>4</sup>

Teeth with dens invaginatus may have esthetic compromise, occlusal problems, early development of caries and subsequent necrosis of the pulp,<sup>5</sup> or tooth impaction.<sup>6</sup> The treatment of dens invaginatus depends on the degree of invagination and morphological abnormalities, and may include prevention of dental caries and dental restoration to more radical procedures, such as endodontic treatment<sup>5</sup> or extraction of the affected tooth.<sup>1,6,7</sup>

The early diagnosis of all forms of dens invaginatus is fundamental for the correct treatment. In some cases, cone beam computed tomography (CBCT) might be necessary in addition to clinical and conventional radiograph examinations for a more precise diagnosis of tooth morphology.<sup>8</sup> The purpose of this presentation is to report a rare case of a radicular dens invaginatus where clinical, radiographic, tomographic, and histological analysis were of fundamental importance for its correct diagnosis and treatment.

## CASE REPORT

A 13-year-old Caucasian boy was referred to the Pediatric Dentistry Clinic of the Faculty of Dentistry, University of São Paulo, Brazil, complaining of pain in the mandibular anterior region of an absent tooth. The patient's medical and family histories were irrelevant and there was no apparent systemic manifestation. Additionally, no history of orofacial trauma or unusual childhood diseases were reported.

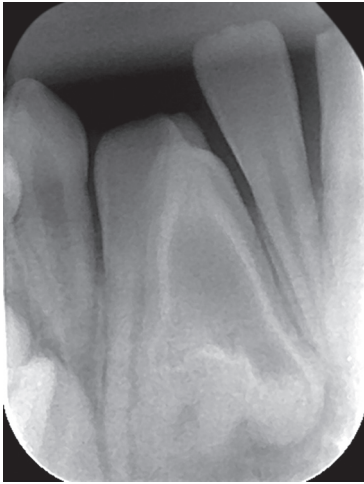<sup>1</sup>Postgraduate Student, <sup>2-4,6</sup>Professor, <sup>5</sup>Surgeon

<sup>1-3,6</sup>Department of Pediatric Dentistry, School of Dentistry of Ribeirao Preto, University of São Paulo, Ribeirão Preto, São Paulo, Brazil

<sup>4</sup>Department of Stomatology, Public Health and Forensic Dentistry, School of Dentistry of Ribeirao Preto, University of São Paulo, Ribeirão Preto, São Paulo, Brazil

<sup>5</sup>Private Practice, Ribeirão Preto, São Paulo, Brazil

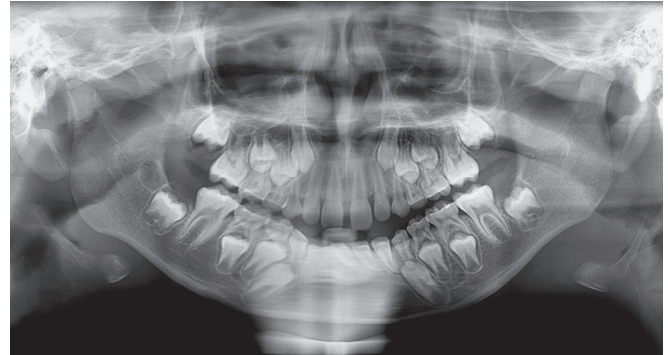**Corresponding Author:** Ana PD Moreno, Postgraduate Student Department of Pediatric Dentistry, University of São Paulo, School of Dentistry of Ribeirao Preto, Preto, São Paulo, Brazil, Phone: 1633153995, e-mail: apaulamoreno@hotmail.com



**Fig. 1:** Periapical radiograph showing the intraosseous position and abnormal morphology of the dental element, highlighting the presence of a radiopaque line internally coating the amorphous structure

The extraoral examination revealed no significant findings. Clinical intraoral examination revealed a mixed dentition, the permanent right mandibular lateral incisor was absent, and that the gingiva in this region was erythematous and edematous. Periapical radiograph revealed that the right mandibular lateral incisor was localized in an intraosseous position and presented an anomalous morphology (Fig. 1). The panoramic radiographic examination showed the normal development of all other teeth (Fig. 2). A small-volume three-dimensional (3D) CBCT scanner confirmed the presence of an uncommon morphology of the right mandibular lateral incisor (Fig. 3).

After clinical, radiographic, and tomographic examination, three diagnosis hypothesis were suggested: gemination, fusion with a supernumerary tooth, or

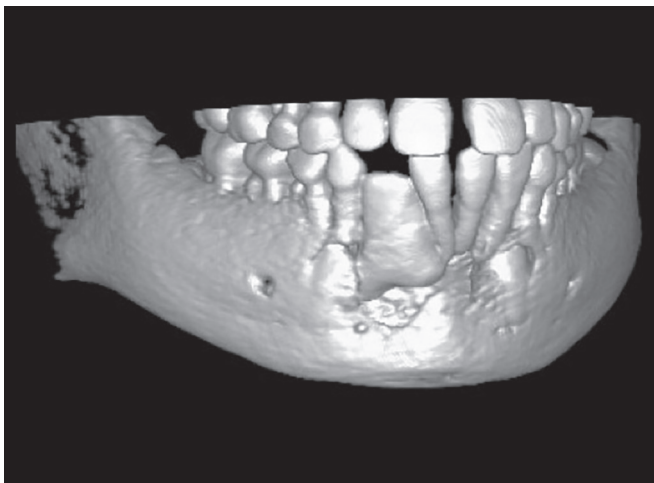


**Fig. 2:** Panoramic radiograph showing a normal feature in the structure and development of other dental elements

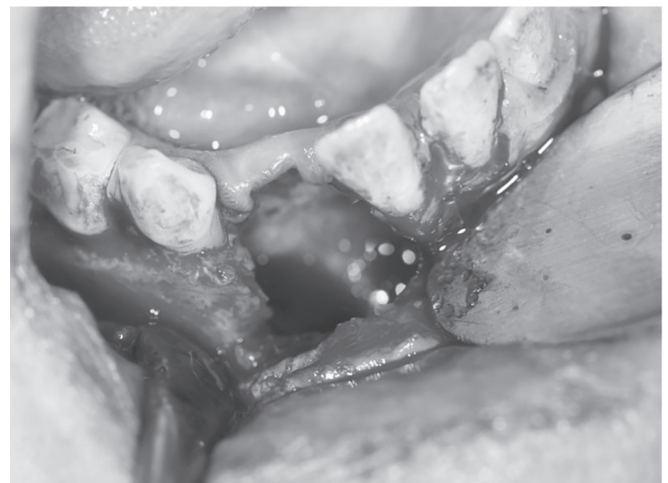radicular dens invaginatus. The periapical radiograph showed the presence of an area of radiopacity similar to enamel coating inside the malformation (Fig. 1). The CT scan also showed, in more detail, the radiopacity presence similar to enamel in the radicular region, in oblique and coronal sections, which contributed to the diagnosis of dens in dente (Fig. 3).

For the treatment of the case, the possibility of surgical treatment, orthodontic traction, and dental reanatomization was evaluated. However, due to the abnormal teeth morphology and the impossibility to perform an orthodontic traction and restoring of the tooth, we choose dental extraction. After written consent from the parents of the patient and surgical planning with tomographic examination, we performed the dental extraction under local anesthesia (Fig. 4).

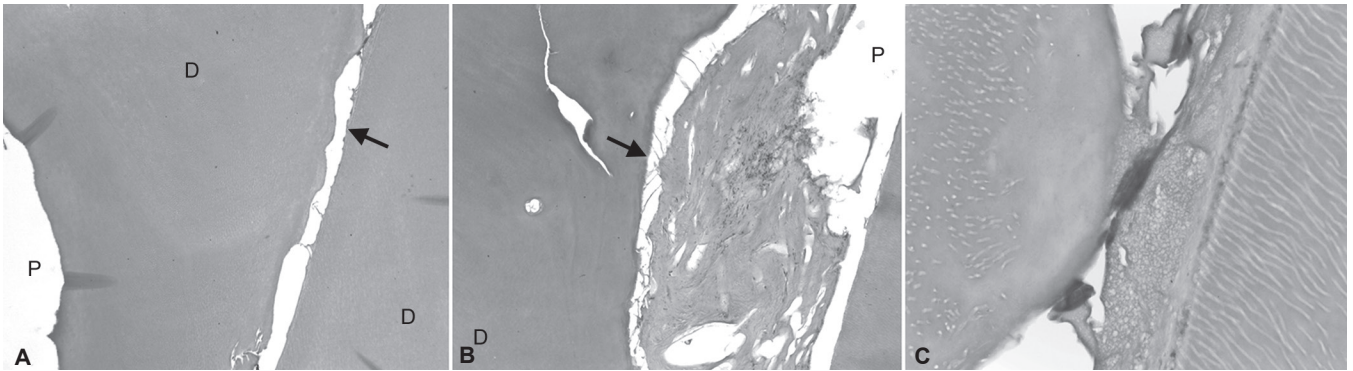
A diagnosis of radicular dens invaginatus was confirmed after histological examination of the tooth. The microscopic analysis of the specimen showed a central irregular cavity, which corresponded to the pulp cavity (arrow), and at the periphery, a narrow channel with faulty



**Fig. 3:** Three-dimensional tomographic image reproduction of the patient's jaw, showing the presence of the lateral incisor with an abnormal morphology



**Fig. 4:** Clinical aspect of the region immediately after extraction of the dental element, showing the large area occupied by the anomalous tooth and thin cortical bone, proving the impossibility of orthodontic traction



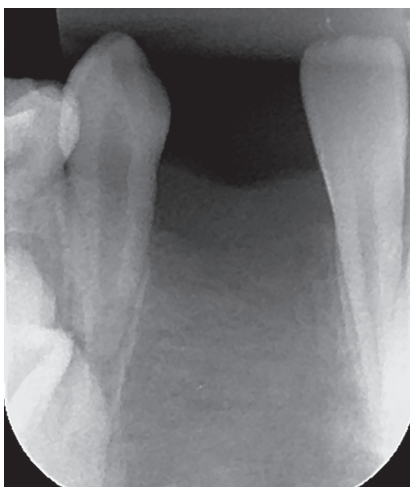
**Figs 5A to C:** (A) Histological image showing dentin (D), pulp cavity (P) containing remnants of pulp tissue, showing the vitality of the dental element; (B) histological image showing a narrow channel at the level of root dentin containing irregular organization of the dentin; and (C) histological image showing basophilic area between the dentinal tissue, compatible with dental enamel. Also it shows a atubular area of dentin tubules and even dentinal tubules in close contact with odontoblasts

walls circumventing the root dentin (arrowhead) was observed (Fig. 5A). Following the microscopic analysis in coronal direction, we noticed the irregular organization of the dentin surrounding the narrow channel located at the level of the root dentin (arrowhead) (Fig. 5B). The close-up view of Figure 5A (the upper right area) shows irregular dentinal canaliculus, atubular dentin area, and amorphous basophilic mineralized tissue consistent with enameloid. Focally, the narrow channel located at the level of the root dentin displayed fibrous connective tissue reminiscent of dental pulp exhibiting irregular dentinal canaliculus in close contact with cytoplasmic processes reminiscent of odontoblasts (Fig. 5C).

At 6 months follow-up, the patient reported no Symptoms and the surgery area was filled with bone (Fig. 6). The patient was then referred to Orthodontic treatment.

## DISCUSSION

This study reports a rare case of dens invaginatus (type IIIb) affecting one mandibular lateral incisor in a boy



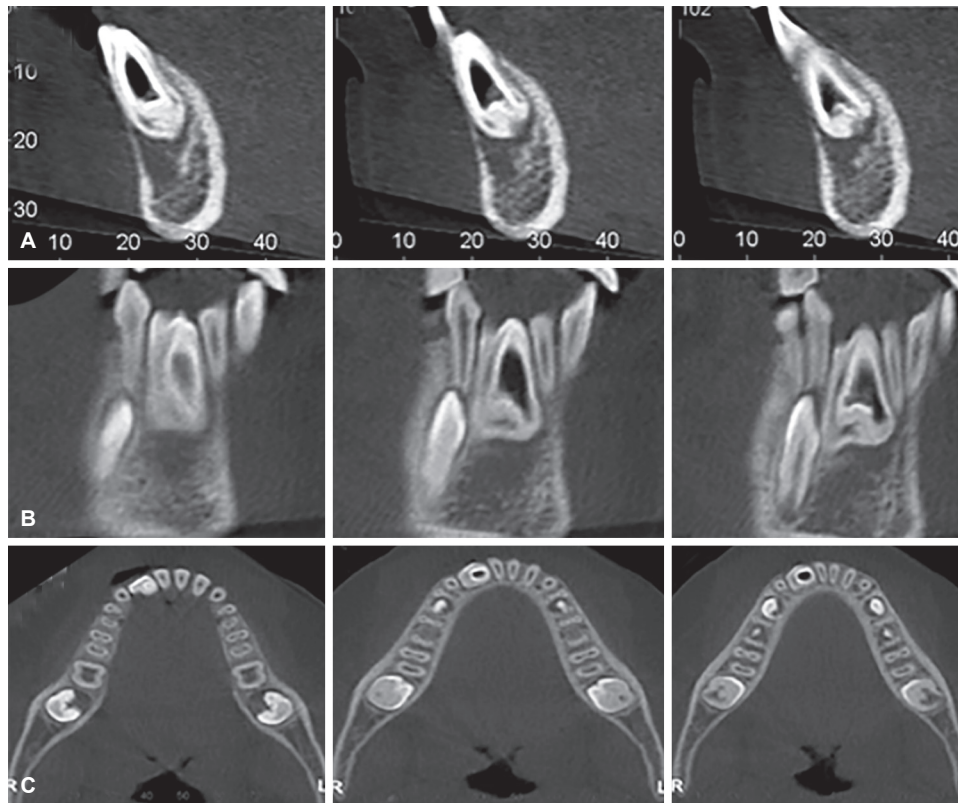
**Figs 6:** Periapical radiograph performed after 6 months of follow-up of the case showing the area filled with bone tissue

9 years and 3 months old. There was presence of painful symptoms and the clinical aspect covered an area of edema and erythema of the mucosa in the mandibular anterior region. Through imaging studies that included periapical radiographs, panoramic radiography, and 3D CBCT, we could suggest the diagnosis of dens invaginatus, gemination, fusion with a supernumerary tooth, or radicular dens invaginatus. The malformed dental element had an altered morphology, was exacerbated in size, and had intraosseous characteristics that hindered the option of the same conservative treatments, therefore, indicating an extraction of the element. The definitive diagnosis of dens invaginatus type IIIb was made by biopsy and histological analysis of the tooth. The most frequently affected tooth by dens invaginatus is the upper lateral incisor and there is a predilection for this dental anomaly in female patients by three-fold.<sup>1</sup> However, in this case, the affected tooth was a lower lateral incisor of a boy.

Dens invaginatus is diagnosed more often in routine clinical examinations, yet generally it does not cause symptoms to patients. If the concerned tooth is erupted, it may or may not show changes to the shape of the crown (peg-shaped, barrel-shaped, or dilated) or with a deep groove called palatal foramen blind. In affected unerupted teeth, the diagnosis is by routine radiographic examination.<sup>1</sup> The dens invaginatus can cause several complications to the patient.

In already erupted teeth, the most common manifestations are related to greater predisposition to caries by biofilm accumulation in the area of invagination and consequent ease for damage-associated pulp.<sup>2,5,9-11</sup> Moreover, they can cause occlusal traumas and esthetic effects.<sup>5</sup> In unerupted teeth affected by dens invaginatus, the most common sequelae are related to tooth eruption, as tooth impaction, retention or deviations in the eruption path of neighboring teeth, or occurrence of dentigerous cysts.<sup>1,12</sup> Less often, there are reports of painful symptoms and other symptomatology in an unerupted dens





**Figs 7A to C:** (A) Oblique cuts of CT showing a radiopaque line compatible with enamel around the amorphous mass throughout extension; (B) coronal sections of CT showing a radiopaque line extending to the apical port; and (C) axial sections of computed tomography showing radiopacity compatible with enamel in the radicular portion

invaginatus,<sup>13</sup> with the occurrence of pain and swelling in the affected region as in this case. In this case, the abnormal shape and size increase of the tooth in all dimensions contributed to the element not following a normal eruption process. Similarly, some authors also reported cases of impacted radicular dens invaginatus.<sup>6,12</sup>

Radiographic analysis allowed the observation of an area with high radiopacity compatible with enamel around every dental element, including the radicular portion, a characteristic also observed by other authors,<sup>10</sup> which contributed to ruling out the possibility of this amorphous dental element, the gemination tooth, or the fusion with a supernumerary tooth. To obtain further evidence for the diagnosis, and allow the surgery to be performed accurately and safely, we nominated for CBCT.

The test was observed in oblique slices (Fig. 7A) and coronal (Fig. 7B), a line with radiopacity similar to enamel in the radicular region bypassing the amorphous mass and extending to apical portions along with a low density region, compatible with a cystic formation. In the axial slices, it was also possible to verify the presence of this radiopacity compatible with enamel in the radicular portion (Fig. 7C). In this case, the CT has contributed to diagnosing radicular dens invaginatus, as reported by other authors.<sup>9,12,14</sup> However, confirmation

of the diagnosis of type IIIb dens invaginatus could be completed only after histopathological analysis, which revealed the presence of an irregular central cavity that corresponded to the pulp cavity, containing remnants of pulp tissue, and at the periphery we observed a narrow channel with faulty walls circumventing the root dentin.

In the presence of unerupted dens invaginatus, there must be early dental planning, where you can choose to keep or not keep the affected tooth. In the case described, extraction was performed on the dental element, similar to other cases in the literature.<sup>1,12</sup> This treatment was necessary due to the presence of painful symptoms, regional edema caused by a cystic lesion in addition to the impossibility of orthodontic traction of the element because of its highly altered morphology. For surgical treatment, the use of the CT images also allowed predictability in surgical planning, providing greater security for such a procedure.

## REFERENCES

1. Hülsmann M. Dens invaginatus: aetiology, classification, prevalence, diagnosis, and treatment considerations. *Int Endod J* 1977 Mar;30(2):79-90.
2. Beena VT, Sivakumar R, Heera R, Rajeev R, Choudhary K, Panda S. Radicular dens invaginatus: report of a rare case. *Case Rep Dent* 2012 Jul;871937.

3. Oehlers FAC. Dens invaginatus I: variations of the invagination process and associated anterior crown forms. *Oral Surg Oral Med Oral Pathol* 1957 Nov;10(11):1204-1218.
4. Pandey SC, Pandey RK. Radicular dens invaginatus – a case report. *J Indian Soc Pedod Prev Dent* 2005 Sep;23(3):151-152.
5. De Rossi A, de Carvalho FK, de Queiróz AM, Bezerra Silva RA, Nelson-Filho P, Bezerra da Silva LA. The treatment of a maxillary lateral incisor with unusual morphology with long-term follow-up. *Int Endod J* 2013 Mar;46(12):1183-1190.
6. Kallianpur S, Sudheendra US, Kasetty S, Joshi P. Dens invaginatus (Type III B). *J Oral Maxillofac Pathol* 2012 May-Aug;16(2):262-265.
7. Silberman A, Cohenca N, Simon JH. Anatomical redesign for the treatment of dens invaginatus type III with open apexes: a literature review and case presentation. *J Am Dent Assoc* 2006 Feb;137(2):180-185.
8. Dinapadu S, Aravelli S, Pasari S, Marukala NR. A rare presentation of bilateral maxillary dens invaginatus diagnosed using cone beam computed tomography. *J Clin Imaging Sci* 2013 Sep;3(Suppl 1):8.
9. Kato H. Non-surgical endodontic treatment for dens invaginatus type III using cone beam computed tomography and dental operating microscope: a case report. *Bull Tokyo Dent Coll* 2013 Aug;54(2):103-108.
10. Chaniotis AM, Tzanetakakis GN, Kontakiotis EG, Tosios KI. Combined endodontic and surgical management of a mandibular lateral incisor with a rare type of dens invaginatus. *J Endod* 2008 Oct;34(10):1255-1260.
11. Stamford I, Kinsky AA, Gaspersic D. Unusual variant of type 3 dens invaginatus in a maxillary canine: a rare case report. *J Endod* 2007 Jan;33(1):64-68.
12. Cantín M, Fonseca GM. Dens invaginatus in an impacted mesiodens: a morphological study. *Rom J Morphol Embryol* 2013 Dec;54(3 Suppl):879-884.
13. Pandey SC, Pandey RK. Radicular dens invaginatus-a case report. *J Indian Soc Pedod Prev Dent* 2005 Sep;23(3):151-152.
14. Neves FS, Pontual AA, Campos PSF, Frazão MAG, De Almeida SM, De Moraes FMRP. Radicular dens invaginatus in a mandibular premolar: cone-beam computed tomography findings of a rare anomaly. *Oral Radiol* 2013;29:70-73.