

A Pink Smile: Depigmentation Using Diode Laser and Surgical Scalpel

Shiny Inasu¹, Biju Thomas²

ABSTRACT

A smile can bring happiness into one's life and also create positivity in the surrounding environment. Black or brown gums is a very common problem among all races of men and women that one complains to a periodontist. This dark color appearance of gums is due to hyperactivity of melanin cells found in the gingival tissue. Different procedures are in practice for gingival depigmentation such as scalpel gingivectomy, cryosurgery, laser with different wavelength, chemicals, electrosurgery, bur abrasion, etc. In this case report, depigmentation procedure is being carried out using surgical scalpel and diode laser and to find out which technique is effective and provide less postoperative discomfort.

Keywords: Depigmentation, Healing, Laser, Periodontist, Smile, Surgery.

International Journal of Experimental Dental Science (2021): 10.5005/jp-journals-10029-1224

BACKGROUND

A smile can bring happiness into one's life and also create positivity in the surrounding environment. However, some people try to hide their smiles or not show much dentition due to the dark appearance of their gums. Black or brown gums are considered as one of the most common problems that one complains to a periodontist.¹ An attractive and beautiful smile is gained by two essential components: gingival appearance and health of gingival tissues, as a result, for the need of a pleasant and confident smile, removal of these dark appearing pigmented gingiva is an essential procedure that a periodontist should be taken into consideration.¹

The normal color of gingiva is described as "coral pink".² Gingival color is determined by the number of factors such as the thickness of the epithelium, number and size of blood vessels, degree of keratinization, pigment cells such as melanin, found in suprabasal and basal cell layers of the epithelium.^{3,4} However, among some men and women, the color of gingiva appears as dark or light brown or black patches due to the excessive deposition and hyperactivity of these melanotic cells in the epithelium.⁵

Melanin is an endogenous, non-hemoglobin-derived from melanocyte cells,⁶ a brown pigment considered to play a protective role in gingival in the animation process. However, discoloration of gingiva is one of the symptoms in some systemic conditions such as Albright's syndrome, Addison's disease, Kaposi's sarcoma, and melanoma, prolonged administration of certain drugs especially antimalarial agents and tricyclic antidepressants endocrine disturbance.^{7,8} Therefore, before any depigmentation treatment, the cause of pigmentation needs to be determined.

Dental esthetics plays an important role in the appearance of patients' smiles, as the esthetic awareness is increasing in demand and also different procedures to achieve it.

Gingival depigmentation can be done by various methods such as surgical methods using a scalpel, bur abrasion method, electrosurgery, lasers with different wavelength such as carbon dioxide (10.600 nm), diode (810 nm), Neodymium:Yttrium Aluminum Garnet (1.064 nm), and Erbium:YAG (2.940 nm) lasers, cryotherapy. Each procedure varies in its technique, healing time, time taken for the procedure, and treatment cost.¹

^{1,2}Department of Periodontics, Nitte (Deemed to be University), AB Shetty Memorial Institute of Dental Sciences, Mangaluru, Karnataka, India

Corresponding Author: Shiny Inasu, Department of Periodontics, Nitte (Deemed to be University), AB Shetty Memorial Institute of Dental Sciences, Mangaluru, Karnataka, India, Phone: +91 9986672589, e-mail: shinyimd@gmail.com

How to cite this article: Inasu S, Thomas B. A Pink Smile: Depigmentation Using Diode Laser and Surgical Scalpel. *Int J Experiment Dent Sci* 2021;10(1):41-44.

Source of support: Nil

Conflict of interest: None

The disadvantage of the gingival depigmentation procedure is the repigmentation. Repigmentation refers to the reappearance of melanin pigment after a period of clinical depigmentation.⁹ This occurs due to the migration of active melanocytes from adjacent pigmented tissues to the surgically treated areas. However, this migration of cells can be eliminated by the removal of melanin from the interdental papilla and free gingiva.⁹

This study aimed to compare gingival depigmentation techniques using diode laser and surgical scalpel and the patient response to these procedures.

CASE DESCRIPTIONS

Case 1

A 28-year-old male patient reported to the Department of Periodontology, AB Shetty Memorial Institute of Dental Sciences, Deralakatte, Mangaluru, with a chief complaint of dark gums on the upper and lower region. The patient was systematically healthy, with no history of smoking, any systemic condition, or taking any drugs. After a clear explanation and understanding of the surgical treatment, informed consent was obtained from the patient.

Phase I therapy that involves non-surgical periodontal therapy such as full mouth scaling was done before surgical treatment.

Surgical Procedure

Initially, local anesthesia containing 2% lidocaine hydrochloride with adrenaline was administered (Fig. 1). With BP (Bard-Parker) blade no: 15, a vertical incision was given initially on distal sides of the first premolar on the right and left sides of the maxillary region. The blade was placed along the long axis of the teeth. A layer of gingival epithelium extending from the free gingival margin to the mucogingival junction from the first premolar on the right side crossing the midline extending up to 1st premolar on the left side was carefully removed, without exposing the underlying bone. Using BP blade no 12, pigmented epithelium in interdental areas was removed carefully. Surgical scissors were used to remove any remaining tissue tags, followed by saline irrigation (Fig. 2). Once bleeding gets controlled, a surgical pack was given extending from 1st premolar on the right side to the 1st premolar on the left side. The patient was recalled after 3 months for follow-up (Fig. 3). Postoperative and oral hygiene instructions, if pain occurs analgesic drug to be taken, were advised to the patient.

Healing was satisfactory and the patient did not complain about postoperative pain. Thus, without melanin pigments, a new epithelium was formed.

Case 2

A 25-year-old male patient reported to the Department of Periodontology, AB Shetty Memorial Institute of Dental Sciences, Deralakatte, Mangaluru with chief complaint black gums and forwardly placed anterior teeth. The patient was not under any medication, no history of any systemic condition, smoking and was

systemically healthy. The patient was explained about the surgical procedure to correct his hyperpigmented gingiva and informed consent was obtained from the patient after a clear understanding of the treatment being given.

Phase I therapy involves full mouth scaling was given before the surgical procedure.

Surgical Procedure

Local anesthesia, 2% lidocaine hydrochloride with adrenaline was infiltrated in the area to be operated on before the procedure (Fig. 4). For safety reasons, the operator and patient were wearing specific eye protection glasses. The diode laser was set to 810 nm wavelength at 0.5–1.5 Watt power in a continuous wave mode. The tip of the laser made of flexible fiber optic quartz was kept in contact with the tissue with light sweeping brush strokes from 1st premolar on right side extending up to left side 1st premolar and adjacent to the tip a high volume suction was kept (Fig. 5). The de-epithelialized blister-formed tissue was then removed with wet, sterile saline gauze. During the procedure, the bleeding of tissues was very less. Saline irrigation was done and later, the treated area was covered with the surgical pack. Postoperative and oral hygiene instructions, if pain persists use of analgesic were advised to the patient. The patient was recalled after 3 months for follow-up (Figs 6 and 7).

DISCUSSION

Dental esthetics is of utmost important treatment choice as it is in increasing demand. Gingival hyperpigmentation is one of the

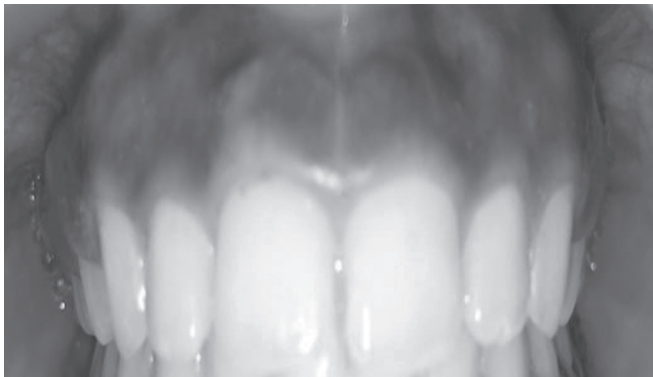


Fig. 1: Preoperative view (Case 1)

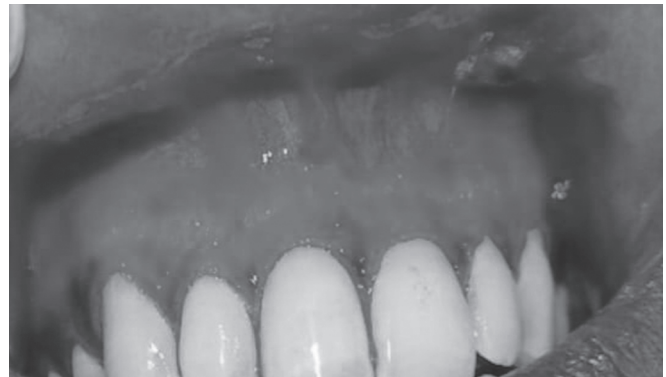

Fig. 2: Surgical view (Case 1)

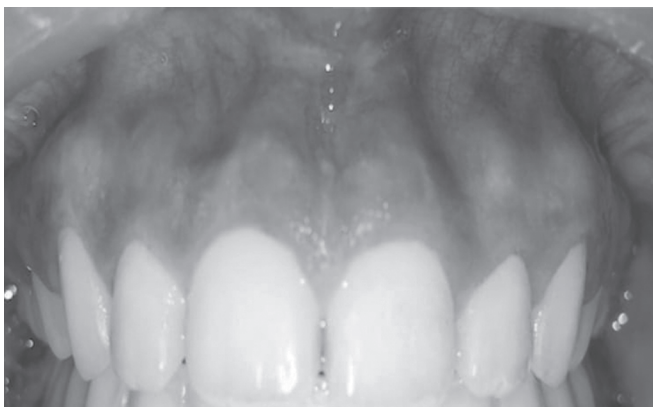


Fig. 3: Postoperative after 3 months (Case 1)

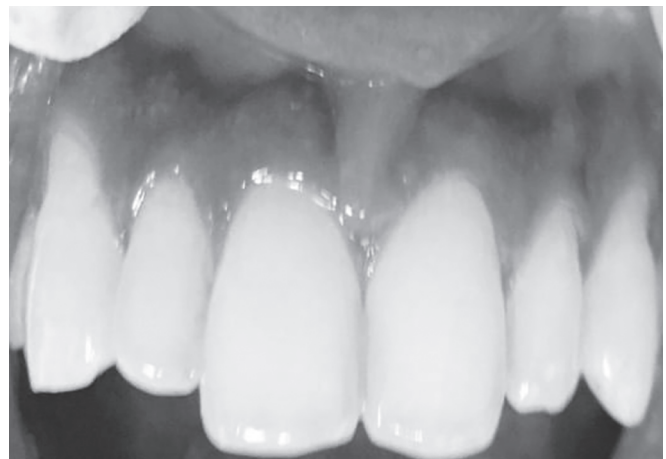

Fig. 4: Preoperative view (Case 2)

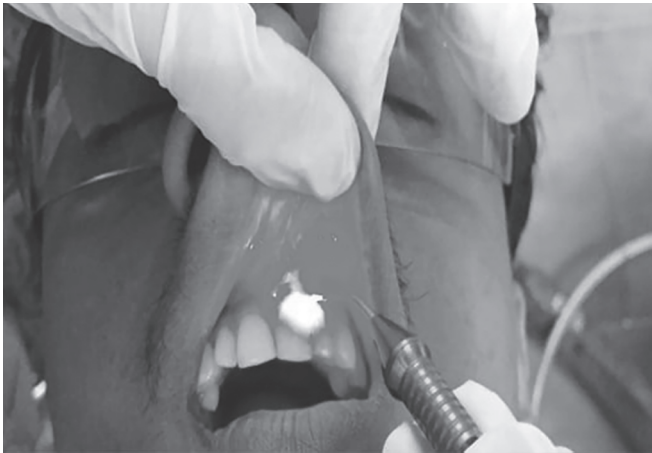

Fig. 5: Surgical procedure using diode laser (Case 2)

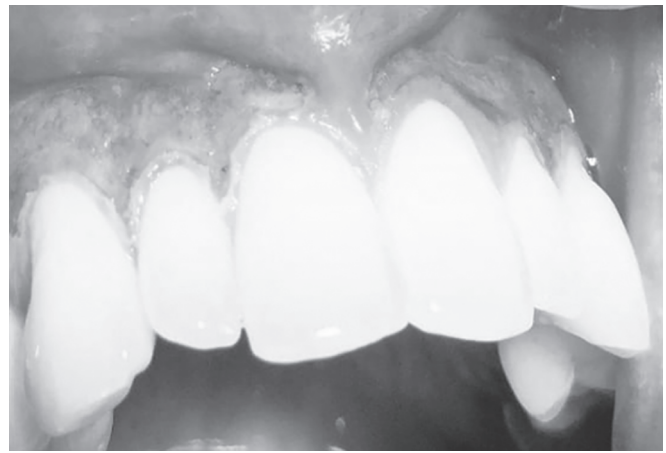

Fig. 6: Immediate postoperative view (Case 2)

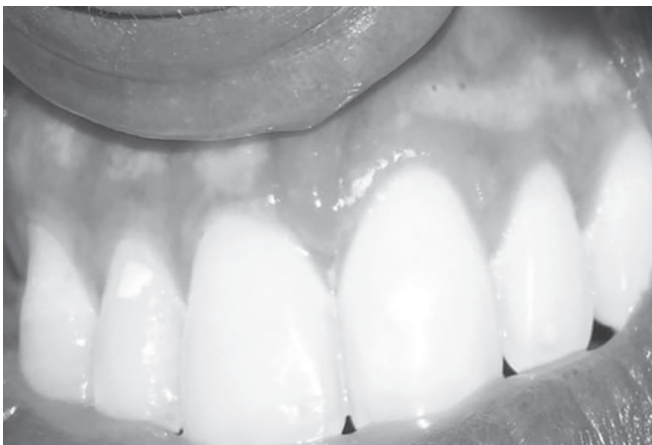

Fig. 7: Postoperative view after 3 month (Case 2)

common problems associated with dental esthetics and there are a variety of procedures to correct this condition. Melanin is found in the basal and suprabasal layer of epithelium produced by melanocytes; hence, the removal of epithelium is required to correct this condition.⁴

In this case report, two techniques have been carried out. The surgical scalpel method is an effective, simple, easier, and affordable method compared with other techniques. Healing takes place by secondary intention and is faster in this method, where newly formed; the non-pigmented epithelium is regenerated within 6 weeks. However, certain disadvantages in this method are postoperative pain, discomfort, excessive bleeding at the time of surgery due to which it takes a prolonged time for this procedure.^{10,11}

To overcome these drawbacks, another method has been put forward, the use of diode laser with 810 nm wavelength, more advanced that specially target the soft tissues. This procedure has special characteristics, where the diode laser has an affinity for melanin and hemoglobin therefore it is a better treatment of choice. Other advantages of this method are faster technique, easier to perform hemostasis is achieved, minimum damage to the periosteum and underlying bone, minimal bleeding during surgery, absence of postoperative pain and swelling, good patient satisfaction. Newly formed re-epithelization occurs after

1–2 weeks and is completed by the end of 4 weeks. However, the disadvantages of this technique are healing is delayed, hence regeneration of new epithelium is delayed, treatment is expensive, chances of bone exposure are more.^{1,12}

The present study did not show any significant difference in healing or postoperative pain of surgically treated areas of the gingiva, although healing took place faster in surgical technique compared with the diode laser technique.

CONCLUSION

People are more concerned about their smiles and esthetic appearance in these recent days. Gingival hyperpigmentation can be eliminated by a variety of surgical techniques. However, the use of a surgical scalpel is considered a more effective and low cost of treatment. In this comparative study, both the surgical technique and use of laser were found to be effective. However, patients should be informed about the possibility of recurrence of the pigmentation before carrying out the procedure.

ACKNOWLEDGMENTS

We would like to thank both patients for being supportive throughout the treatment and follow-up period.

REFERENCES

1. Bhardwaj A, Grover HS, Lal S. Gingival depigmentation with scalpel and diode laser. *World J Dent* 2012;3(4):359–362. DOI: 10.5005/jp-journals-10015-1190.
2. Suchetha A, Shahna N, Divya Bhat AS, et al. A review on gingival depigmentation procedures and repigmentation. *Int J Appl Dent Sci* 2018;4(4):336–341.
3. Mokeem SA. Management of gingival hyperpigmentation by surgical abrasion: report of three cases. *Saudi Dent J* 2006;18(3):162–166.
4. Patil KP, Joshi V, Waghmode V, et al. Gingival depigmentation. A split mouth comparative study between scalpel and cryosurgery. *Contemp Clin Dentis* 2015;6(1):S97. DOI: 10.4103/0976-237X.152964.
5. Grover HS, Dadlani H, Bhardwaj A, et al. Evaluation of patient response and recurrence of pigmentation following gingival depigmentation using laser and scalpel technique: a clinical study. *J Indian Soc Periodontol* 2014;18(5):586–592. DOI: 10.4103/0972-124X.142450.
6. Thangavelu A, Elavarasu S, Jayapalan P. Pink esthetics in periodontics- gingival depigmentation: a case series. *J Pharm Bioallied Sci* 2012;4(Suppl 2):186–190. DOI: 10.4103/0975-7406.100267.

7. Dummett CO. A classification of oral pigmentation. *Mil Med* 1962;127(10):839–840. DOI: 10.1093/milmed/127.10.839.
8. Leston JM, Santos AA, Varela-Centelles PI, et al. Oral mucosa: variations from normalcy. Part II *Cutis* 2002;69(3):215–217.
9. Gufran K. A comparative evaluation of two different techniques for esthetic management of gingival melanin hyperpigmentation: a clinical study. *J Dent Res Rev* 2016;3(1):13. DOI: 10.4103/2348-2915.180109.
10. Peters E, Gardner DG. A method of distinguishing between amalgam and graphite in tissue. *Oral Surg, Oral Med, Oral Pathol* 1986;62(1):73–76. DOI: 10.1016/0030-4220(86)90073-3.
11. Chacko LN, Abraham S. Gingival melanin de pigmentation for aesthetic correction. *BMJ Case Rep* 2014;2014(1):bcr2014205711. DOI: 10.1136/bcr-2014-205711.
12. Soliman MM, Al Thomali Y, Al Shammrani A, et al. The use of soft tissue diode laser in the treatment of oral hyper pigmentation. *Int J Health Sci* 2014;8(2):133. DOI: 10.12816/0006079.